

## Case Report

# Signet ring cell carcinoma of the colon in a 10 year-old boy

Irene, Ketut Ariawati

Signet-ring cell carcinoma (SRCC), a variant of adenocarcinoma, is defined by the presence of more than 50% of tumor cells with prominent intracytoplasmic mucin.<sup>1</sup> Primary gastrointestinal malignancies constitute only 1% of pediatric neoplasms and 0.34% take the form of colon carcinoma. It is a very rare disease in persons under 17 years of age, 94% of which is found in children > 9 years of age.<sup>1-4</sup> In contrast to adults, approximately 50% of colon carcinoma cases in children are the highly malignant mucin-producing adenocarcinoma type.<sup>4</sup> The typical signet-ring cell has a large mucin vacuole that fills the cytoplasm and pushes the nuclei to the side, thereby giving the cells their signature histologic appearance.<sup>5,6</sup> Carcinoma of the colon during childhood has been associated with familial polyposis and ulcerative colitis. However, carcinoma arising *de novo* is the most common type.<sup>2,3</sup> Risk factors include a high caloric diet rich in animal fat, sedentary lifestyle, smoking, alcohol consumption, low vegetable fibre consumption, chronic inflammatory bowel disease, ulcerative colitis, Crohn's disease, and polymorphism in key enzymes of injurious compounds.<sup>5</sup>

SRCC may be asymptomatic, but in most pediatric patients, symptoms of various degrees of obstruction are common and preceded by changes in bowel habits. Abdominal masses are present in 60% of cases at the time of diagnosis, and abdominal distention in 50%. A definitive diagnosis is based

on histological biopsy.<sup>4,5,7</sup> Surgical resection is the indicated treatment for most colon carcinomas, but most tumors are incurable, due to extensive lymphatic or portal venous spread.<sup>4,8</sup> Approximately 20% of patients present as an emergency case, requiring an urgent operation for a tumor-related complication, such as bowel obstruction.<sup>8</sup> 5-fluorouracil has been reported to be an effective cytotoxic agent.<sup>4</sup> SRCC of the colon has a generally poor prognosis due to late diagnosis and its highly malignant nature. The 5-year survival rate is less than 10%.<sup>2,4</sup> We present a child with SRCC, as the first case ever reported in Bali.

## The Case

A 10 year-old boy was referred to Sanglah Hospital on September 27, 2008 with abdominal pain as his chief complaint. The pain was suspected to be due to gastritis. Approximately a month prior to admission, the patient had suffered from abdominal pain that recurred every 1 to 2 hours, lasting 15-30 minutes per

---

From the Department of Child Health, Faculty of Medicine, Udayana University, Sanglah Hospital, Denpasar, Indonesia.

**Reprint requests to:** Irene, Department of Child Health, Faculty of Medicine, Udayana University, Sanglah Hospital, Jl. Pulau Nias, Denpasar, Bali 80114, Indonesia. Ph. 62-361-244038. Fax. 62-361-244038. E-mail: irenewidodo@yahoo.com

episode. The pain was first located in the epigastrium, and later diffused to the whole abdominal area, so that the patient was unable to determine the exact location. He also reported more severe pain at night that was partially relieved by meals or vomiting.

Three days after his first complaint, his stools became hard in consistency, small in caliber and dark in color. He described them as "goat's stools" because of the close resemblance. The passage of the hard stools alternated with loose liquid stools. There was no history of trauma. After taking medications prescribed by a local pediatrician, the pain intensity decreased, but the alternate hard and loose stools persisted. The parents subsequently took the patient to the same pediatrician four times. Each visit was after the patient finished the course of medications, and new medications were then prescribed. Despite the multiple courses of medications, the pain intensified. The alternating hard and loose stools persistently occurred twice a day. There was no history of passage of blood or masses. The patient experienced a 4-kilogram weight loss since the onset of abdominal pain, presumably caused by loss of appetite. There was no significant history of constipation, chronic diarrhea, vomiting, fever, abdominal distention, tenesmus, or painful urination. Due to the illness, his school performance dropped dramatically.

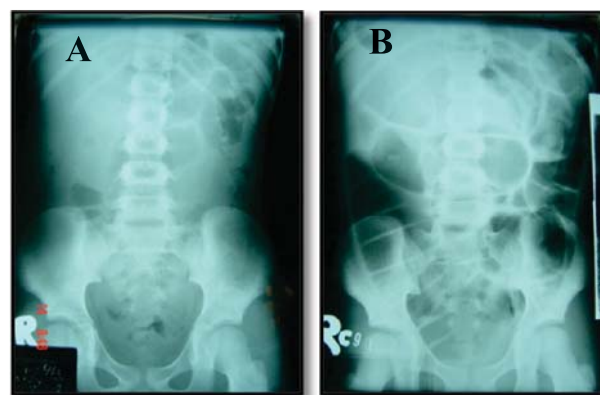
Two days prior to his referral to Sanglah Hospital, the patient suffered from excruciating abdominal pain and was admitted to Klungkung Hospital. He was diagnosed with suspected gastritis and treated accordingly. On the day of the referral, there was greenish vomiting and no pain relief. Thus, the patient was referred to Sanglah Hospital for further evaluation and treatment.

He was born full term, spontaneously, and his birth weight was 3,000 grams. He did not take any prior medications for specific diseases. There was also no history of receiving irradiation, alcohol consumption or frequent exposure to cigarette smoke. There was no family history of significant abdominal pain, bloody stools, cancer or polyps. His immunization history was complete, according to the Indonesian Society of Pediatricians' recommended immunization schedule. Based on 24-hr recall history, the patient's food intake (450 kcal) was far less than his actual needs, according to the recommended daily allowance (2040-2295 kcal). The daily intake of vegetables and

fruit fiber was minimal compared to fried and instant prepackaged food. Daily activities and development prior to illness were normal.

Physical examination revealed an alert boy, who appeared inactive and in pain. His pulse was regular at 98 beats per minute, respiratory rate 22 beats per minute and axillary temperature 36.8°C. His body weight, body height and upper arm circumference were 19 kg, 128 cm and 15.5 cm, respectively, suggesting undernourishment. The conjunctivae were not anemic or icteric and there were no palpable cervical nodes. Chest examination revealed normal findings. The abdomen was not distended with normal bowel sounds. Both liver and spleen were not palpable. There was tenderness only in the epigastric area. There were no signs of ascites, nor palpable or visible masses. The abdomen was soft, with no muscular tensing. Examination of upper and lower extremities showed no deformities, edema or cyanosis. Neurological reflexes and motor strength were normal.

Laboratory investigation revealed a leukocyte count of 11.8 K/ $\mu$ L (neutrophils 66.6%, lymphocytes 25.7%, monocytes 6.5%, eosinophils 1.0%, basophils 0.2%), hemoglobin 12.1 g/dL, hematocrit 36.6 %, and platelet count 351,000/ $\mu$ L. Serum electrolyte examination revealed hyponatremia (125.2 mmol/L). Urine examination was normal. Anti-*Helicobacter pylori* IgG level was positive (28.2 U/mL). Plain abdominal radiograph showed no radiopaque stones and no gastrointestinal dilatation. (Figure 1A)



**Figure 1.** (A) Normal plain abdominal radiograph taken at the first admission. (B) Second plain abdominal radiograph in supine position with total obstructive ileus.

The patient was initially diagnosed with chronic gastritis due to *Helicobacter pylori* infection, undernourishment, and hyponatremia. Medical management included the administration of oral clarithromycin, metronidazole and omeprazole; correction of hyponatremia; and nutritional intervention using rice porridge and liquid meal (Ensure®).

On the sixth day of treatment, the patient was suddenly unable to pass gas or stools. There was abdominal distention and vomiting of previously ingested meals. To exclude acute pancreatitis, amylase examination was done, and the result was within normal limits (23 U/L). The next morning, the abdomen became highly distended and showed visible intestinal contours and peristaltic movement. No gas or stools could be passed and a metallic sound was heard upon auscultation. Digital rectal examination revealed no blood, palpable masses or stool. A second plain abdominal radiograph was taken in a supine position. The radiograph showed dilated small bowel, air-fluid levels, Herring-bone appearance, and no air in the rectum. (Figure 1B) The patient was diagnosed with total obstructive ileus. Hence, explorative laparotomy was performed.

During exploratory surgery, a tumor was found in the ascending colon. Tumor resection was done, followed by end-to-end anastomosis between the ileum and transverse colon. Liver evaluation showed no palpable tumor. A mesentery gland was also taken for pathological examination. Post-operatively the patient was considered to have had an ascending colon tumor resection with dextra hemicolectomy and end-to-end ileocolotrans-anastomoses. Gross pathological examination revealed a mass 30 x 10 x 7 cm in size, as shown in Figure 2. Five centimeters from the distal border, a narrowing of the lumen and a circular thickening of the colon wall were found, containing a solid white mass with indistinct borders. Just proximal to the narrowing was a dilated lumen with thin walls (0.2 cm). There were no nodules found in the mesocolon.

Infiltration of anaplastic cells was found in the thickened ascending colon wall, the vermiform appendix, and two of the adjacent lymph nodes. PAS staining confirmed the presence of mucin in the signet ring cells, and a positive cytokeratin immunohistochemical staining confirmed the epithelial origin of the cells. (Figure 3)




Figure 2. Gross pathological examination of the tumor.

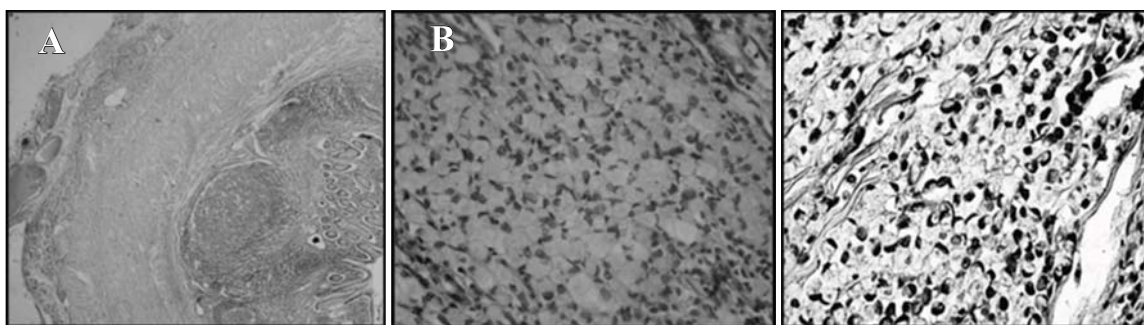


Figure 3. (A) Microscopic pathological examination showed the presence of more than 50% SRCC (B) stained positive with PAS and (C) cytokeratin staining.

A thoraco-abdominal CT-scan with radioactive contrast after the surgery showed no metastasis in the liver or paraaorta, and no dilatation of the stomach or the rectum to the descending colon. The CEA level after surgery was negative (1.2 mg/mL). The patient's carcinoma was categorized as stage IIIB and he was treated with 6 cycles of chemotherapy based on the Mayo Clinic Regimen for colorectal carcinoma, which included 5-fluorouracil (425 mg/m<sup>2</sup> intravenous) and folinic acid (20 mg/m<sup>2</sup> intravenous).

## Discussion

Colon cancer has been said to be the third most prevalent neoplasm in the world across all ages, but over 90% of cases occur after 50 years of age, and only 1% occur in persons under 30 years of age.<sup>9-11</sup> Primary gastrointestinal malignancies constitute only 1% of pediatric neoplasms with 0.34% taking the form of colon carcinoma.<sup>1,4</sup> The incidence of colorectal carcinoma in boys is twice as high as in girls.<sup>4</sup> Approximately 50% of childhood colon carcinomas are highly malignant mucin-producing adenocarcinomas, including signet ring cells (1-2% of all tumors).<sup>4,12</sup> The proportion of patients with distant metastases at diagnosis is approximately 60%.<sup>10</sup>

In general, colorectal carcinomas are believed to be the result of complex interactions between environmental and genetic factors. Based on the course of development, there are three groups of colorectal carcinomas: the inherited group (less than 10% of all cases), the sporadic group (70%), and the familial group (20%).<sup>9</sup> In well-defined colorectal carcinoma cases, predisposing syndromes account for only 3-5% of all colon cancer and include Peutz-Jeghers syndrome, familial juvenile polyposis, hereditary mixed polyposis syndrome, hereditary non-polyposis colon cancer, Lynch syndrome, and familial adenomatous polyposis.<sup>10,12</sup> For children and adolescents there is no evidence that a family history of gastrointestinal carcinoma, familial cancer syndromes, or familial juvenile polyposis confer a great risk for developing colorectal carcinoma before the age of 20.<sup>10</sup> In most cases, colorectal carcinomas arise *de novo*.<sup>4</sup> Predisposing risk factors for the development of colorectal carcinoma include high fat intake, sedentary lifestyle, cigarette smoking, consumption

of red meat and alcohol, increased bile salt pool, higher stool pH, inflammatory bowel disease and prior radiation exposure. The use of cyclooxygenase-2 inhibitors and diets with increased fiber and calcium are believed to reduce the risk.<sup>5,9,10,12</sup>

The earliest morphological precursor of epithelial neoplasia is the aberrant crypt focus (ACF). Progression from ACF through adenoma to carcinoma characterizes carcinogenesis in the colon. The development of most colorectal carcinomas begins in epithelial cells with a mutation inactivating the adenomatous polyposis coli (APC) tumor suppressor gene. This inactivation interferes with E-cadherin homeostasis and gene transcription, causing clonal accumulation of additional genetic alterations, including activation of proto-oncogenes such as *c-myc* and *ras*, and inactivation of additional suppressor genes, such as those on chromosome 18 and the *TP53* gene of chromosome 17. The mutated gene fails to regulate p21WAF1/CIP1 cyclin-dependent kinase inhibitor, which complexes with proliferating cell nuclear antigens, leading to apoptosis. The APC gene mutation results in inactivation of APC/beta-catenin pathway, causing growth of adenomas. Juvenile polyps typically occur in children, but rarely develop intraepithelial neoplasia, unless the APC/beta-catenin pathway is inactivated. Patients with chronic inflammatory bowel disease and chronic colitis may develop dysplastic lesions. The spectrum of genetic susceptibility is broad, ranging from well-defined autosomal dominantly inherited syndromes with known germline genetic mutations to ill-defined familial aggregations.<sup>5,8</sup>

Colon carcinoma is defined as a malignant epithelial tumor of the colon. Only tumors that have penetrated through the muscularis mucosae into the submucosa are considered malignant at this site.<sup>5</sup> The histologic forms of colorectal carcinoma include mucinous adenocarcinomas (tumors in which more than 50% of the lesion is composed of mucin), SRCCs (tumors in which more than 50% of cells in the lesion contain intracellular mucin), adenosquamous, medullary, and undifferentiated carcinomas. Signet ring cells can occur within the mucin pools of mucinous adenocarcinoma or as a diffusely infiltrative process with minimal extracellular mucin.<sup>5,10</sup> Most carcinomas are located in the sigmoid colon and rectum, but with an increasing proportion

of proximally-located carcinomas. Carcinoma of the proximal colon tends to grow as exophytic masses, while that of the transverse and descending colon grow as endophytic and annular masses, thus encircling the bowel. In contrast to rectal carcinomas, colon carcinomas can extend directly to the serosal surface. Peritoneal carcinomatosis can be due to perforation and in rare cases, implantation from surgical manipulation. Spread through lymphatic or blood vessels can occur early in the natural history and lead to systemic disease if the muscularis mucosae and the submucosa are invaded. Invasion of the portal vein can also lead to haematogenous dissemination. Adenocarcinomas are graded based on the extent of glandular appearances. Mucinous adenocarcinoma and SRCC by convention are considered poorly differentiated (grade 3).<sup>4,5</sup>

In general, colorectal cancer does not display early signs. In fact, symptoms are often absent until a tumor has grown to a significant size. Unless a tumor complication arises, such as bowel obstruction, symptoms are mostly subtle or uncharacteristic.<sup>8</sup> Reported earliest symptoms of colorectal carcinoma are abdominal pain and changes in bowel habits (alternating periods of constipation and diarrhea).<sup>4,8</sup> Signs of mechanical obstruction are common in children (16%), either partial or complete.<sup>8,9</sup> Carcinoma of the right half of the colon in children is usually large and polypoid. However, because of the fluid state of feces at this site, obstruction is less likely to occur before the tumor grows relatively large.<sup>8</sup> Lethargy, anemia and weight loss tend to occur late in the course of disease. An abdominal mass is present in approximately 60% of patients at the time of diagnosis, and abdominal distention in about 50%.<sup>4</sup> If the carcinoma occurs in the right side of the colon, symptoms include abdominal pain (93.1%), vomiting (51.7%), constipation (16.5%), weight loss (20.7%), blood in stool (13.8%), abdominal distention (3.2%), anorexia (6.9%), diarrhea (6.9%), malaise (3.4%), abdominal mass (10.2%), paleness (3.4%), and no back pain.<sup>2</sup> Enlargement of the supraclavicular nodes is a sign of disseminated gastrointestinal malignancy (Troisier's sign). Hepatomegaly is present if liver metastasis has occurred. Presence of peritoneal signs may indicate tumor perforation. Digital rectal examination is required to determine the exact distance from the anal verge, circumferential

position, mobility against surrounding structures, and the presence of stool, blood, or melena. The patient may present in an emergency setting, when acute symptoms occur as a result of prolonged fasting, nausea or vomiting, and translocation of fluids into the third space during a period of bowel obstruction or after a perforation. Then the patient may present with dehydration, short-term weight loss, acidosis, electrolyte imbalance and sepsis.<sup>8</sup> Symptoms may have been present for periods ranging from 7 to 12 months (median, 3 months) before diagnosis.<sup>3</sup> In our case, the patient suffered from abdominal pain for 1 month, along with vomiting, anorexia, short-term weight loss, alternating hard and liquid stools, undernourishment, and hyponatremia. This patient deteriorated into an emergency state due to complete bowel obstruction. The above physical findings likely related to mechanical obstruction of the bowel.

There are three goals in the evaluation of colorectal cancer: (1) to assess the large bowel with regards to the primary lesion, concomitant lesions, and potential colonic disease (2) to determine whether the tumor has metastasized, and (3) to assess the patient's operability. Investigation methods include rigid proctoscopy and flexible sigmoidoscopy, colonoscopy, contrast enema, CT colonography and MRI. CT scans are used most commonly, with 90% sensitivity and 95% specificity in detecting liver lesions greater than 1 cm. Under special circumstances, a positron-emission tomographic (PET) scan is indicated. If tumor obstruction is present, abdominal x-ray or CT scan typically demonstrate features of bowel obstruction depending on how proximal it is located.<sup>8</sup> In our case, no screening method was done. Due to complete bowel obstruction, an abdominal x-ray was repeated, and signs of obstruction were present. Post-operative CT scan revealed no metastasis.

Bowel obstruction requires urgent intervention to prevent cecal perforation. If colon obstruction is proximal enough, a resection with primary entero-colonic anastomosis, such as right hemicolectomy or subtotal colectomy, may be indicated. Synchronous lesions, which may occur in up to 15% of patients with an obstructing lesion, may be missed and necessitate further intervention in the future. Recently, there has been an attempt to relieve the acute obstruction with the insertion of a self-expanding metallic stent to decompress the prestenotic colon, allowing for patient

stabilization and bowel preparation.<sup>8</sup> In our patient, we found a tumor in the ascending colon, encircling the bowel with a thickened wall and narrowed the lumen. Hence, a right hemicolectomy with proximal margin resection at the distal ileum was performed, followed by end-to-end anastomoses between the ileum and transverse colon.

A definitive histopathological diagnosis can confirm TNM classification.<sup>5</sup> The histopathological appearance of SRCC is similar to goblet cell carcinoid, which originates from neuroendocrine cells. In our case, the tumor presented as a solid white mass with indistinct borders. In the microscopic evaluation, infiltration of anaplastic cells was found in the thickened ascending colon wall, the vermiform appendix, and two of the adjacent lymph nodes. These cells were signet ring cell carcinoma (morphology 8490/3), with TNM classification of pT4 pN1 pM0 (Dukes stage IIIB). Both PAS and cytokeratin staining were positive, indicating the epithelial origin and the presence of intracytoplasmic mucin.

In patients with stage II or III colorectal cancer after potentially curative resection, or with advanced colorectal cancer, the adjuvant and advanced regimen included IV bolus fluorouracil. The regimen includes folinic acid calcium 20 mg/m<sup>2</sup> per day by intravenous injection on 5 consecutive days, and fluorouracil 425 mg/m<sup>2</sup> per day intravenous push over 1-2 minutes after leucovorin for 5 consecutive days. Both drugs are given on days 1-5 every 4 weeks for 6 cycles. Complete response to the regimen has been reported at 0.7%, partial response 14.3%, and stable disease 55.5%. Mean duration of response was 9.4 months, median time to progression 4.7 months, and median survival 12.1 months.<sup>13</sup>

Histopathological features related to poor prognosis include deep infiltration of the layers of the wall, extensive involvement of a particular layer, an infiltrative pattern of the invasive edge of the tumor (in contrast to an expansive pattern), and poor differentiation, including signet ring cell and mucinous adenocarcinoma.<sup>5</sup> The prognosis of SRCC of the colon is generally poor because of late diagnosis and the frequency of high malignancy. The 5-year survival rate is reported to be less than 10%,<sup>4</sup> and has been reported as low as 0%.<sup>10</sup> The disease recurrence is more frequent with SRCCs.<sup>10</sup> We presumed the survival duration of our patient to be 6 months and

15 days from the time of diagnosis. Recurrence was not detected during the course of the treatment.

The diagnosis in this patient was made very late in the course of the disease, when the tumor mass had already grown to significant size, hence causing complete bowel obstruction. The tumor was considered malignant as it had infiltrated the submucosal layer of the colon wall. Early signs were nonspecific, mistaken for chronic gastritis, and treated accordingly. The observed survival duration in this patient was relatively short from the time of the diagnosis, despite having completed 5 out of the pre-programmed 6 cycles of adjuvant therapy. Side effects of the therapy were not apparent. The patient dropped out of the chemotherapy plan approximately one month before the time of death. Recurrence had not arisen during the course of treatment. However, recurrence could not be determined after the patient dropped off the therapy plan.

## References

1. Redkar RG, Kulkarni BK, Naik A, Borwankar SS. Colloid carcinoma of rectum in a 11 year old child. *J Postgrad Med.* 1993;39:218-9.
2. Middlekamp JN, Haffner H. Carcinoma of the colon in children. *Pediatrics.* 1963;32:558-71.
3. Rao BN, Pratt CB, Fleming ID, Dilawari RA, Green AA, Austin BA. Colon carcinoma in children and adolescents. *Cancer.* 1985;55:1322-6.
4. Jones PG, Campbell PE. Carcinoma of the colon and rectum. In: Jones PG, Campbell PE, editors. *Tumours of infancy and childhood.* 1<sup>st</sup> ed. Philadelphia: Blackwell Scientific Publications; 1976. p. 641-9.
5. International Agency for Research on Cancer. Tumours of the colon and rectum. In: Hamilton SR, Aaltonen LA, editors. *WHO classification on tumours: Pathology and genetics of tumours of the digestive system.* 1<sup>st</sup> ed. Lyon: IARC; 2000. p. 104-19.
6. Lee WS, Chun HK, Lee WY, Yun SH, Cho YB, Yun HR, et al. Treatment outcomes in patients with signet ring cell carcinoma of the colorectum. *Am J Surg.* 2007;194:294-8.
7. Jones PG, Campbell PE. Malignant disease in childhood. In: Jones PG, Campbell PE, editors. *Tumours of infancy and childhood.* 1<sup>st</sup> ed. Philadelphia: Blackwell Scientific Publications; 1976. p. 21-31.
8. Kaiser AM, Nunoo-Mensah JW, Beart RW. Tumors of

- the colon. In: Zinner MJ, Ashley SW, editors. *Maingot's abdominal operations*. 11<sup>th</sup> ed. Massachusetts: McGraw-Hill; 2007. p. 625-52.
9. Kelompok Kerja Adenokarsinoma Kolorektal. Insidensi dan pencegahan karsinoma kolorektal. In: Sjamsuhidajat R, Karnadihardja W, Rudiman R, et al., editors. *Adenokarsinoma kolorektal: Panduan pengelolaan*. 1<sup>st</sup> ed. Jakarta: Kelompok Kerja Adenokarsinoma Kolorektal; 2006. p. 5-9.
  10. Furman WL, Hill DA, LaQuaglia M. Colorectal cancer. In: Bleyer WA, Barr RD, editors. *Cancer in adolescents and young adults*. 1<sup>st</sup> ed. Berlin: Springer; 2007. p. 331-40.
  11. Shah RS, Pikale HS, Birmole BJ, Kulkarni BK, Borwankar SS. Adenocarcinoma of the colon in a child. *J Postgrad Med*. 1992;38:81-3.
  12. Riddell RH, Petras RE, Williams GT, Sobin LH. Epithelial neoplasia of the intestines. In: Riddell RH, Petras RE, Williams GT, Sobin LH, editors. *Tumors of the intestines*. 1<sup>st</sup> ed. Washington DC: The Armed Forces Institute of Pathology; 2003. p. 133-62.
  13. Leonard G, Grem J. Colorectal Cancer. In: Boyiadzis MM, Lebowitz PE, Frame JN, Fojo T, editors. *Hematology oncology therapy*. 1<sup>st</sup> ed. New York: McGraw-Hill; 2007. p. 101-18.