

Langerhans' cell histiocytosis: difficulty in establishing diagnosis (a case report)

Annie Kusumadewi, Landia Setiawati, Bambang Permono

Langerhans' cell histiocytosis (LCH), previously called histiocytosis X, demonstrates a broad spectrum clinical and radiological features that may mimic infection as well as benign and malignant tumors, which may be diagnosed accidentally on radiograph.^{1,2} The causes and pathogenesis remain unclear.² Osseous involvements are typically in flat bones, with lesions of skull, pelvis, and ribs accounting for more than half of all lesions. About 30% of lesions are in long bones.¹

The incidence of LCH is estimated to be 0.05-0.5 per 100,000 children per year in the United States, with a slight male predominance. The disease may present at any time from infancy to old age, but the peak incidence is 1-3 years.² There were 12 cases of hystiocytosis at Dr. Soetomo Hospital during 2001-2007.³

The symptoms of limp, pain, with bone lesion in children are also found in osteomyelitis.⁴ Osteomyelitis should be considered in any child with limp, non or decreased use of extremity, focal bony pain, unexplained musculoskeletal swelling, and constellation of fever.⁵ The predominant organism in acute osteomyelitis is *Staphylococcus aureus* followed by *Streptococcus pyogenes*.⁶ Delayed diagnosis and inadequate treatment of an acute osteomyelitis allow the disease develop to become subacute or chronic state. A protracted disease is also seen with organism responsible for low-grade infections such as tuberculosis.⁷ The symptoms and findings of

tuberculosis are systemic in nature.⁸ Because skeletal neoplasm can mimic benign conditions such as osteomyelitis, the possibility of neoplasm must always be suspected.^{9,10} Furthermore, symptoms of skeletal neoplasm are often nonspecific, leading to frequent misdiagnosis.⁹

We present a case of Langerhans' cell histiocytosis that previously diagnosed as tuberculous osteomyelitis, focusing on difficulty in diagnosis.

Case report

A 2-year-old boy was referred by Orthopedic Department to the Pediatric Outpatient Clinic Soetomo Hospital on August 2, 2006, with suspicion of tuberculous osteomyelitis of the iliac and tibial bones. He suffered from limp since 3 weeks preceded by painful gait on the left lower leg 6 months before. Pain was experienced at rest which worsened on

From The Department of Child Health, Medical School, Airlangga University, Surabaya, Indonesia.

Reprint requests to: Annie Kusumadewi, MD, Department of Child Health, Medical School, Airlangga University, Dr. Soetomo Hospital, Jl. Prof Moestopo 6-8, Surabaya 60285. Telp. 62- 31-5501614. Fax. 62-31-5501748. e-mail: annie_kusuma@yahoo.com.

movement. Left leg swelling was found since 2 months prior to admission. Chronic recurrent cough, night sweating, and low grade fever were noted since the last 6 months. Tuberculosis contact was denied. Triple anti-tuberculosis had been administered for 2 months, without clinical improvement.

Physical examination on admission revealed an irritable boy with body weight of 10 kg (<3rd percentile, %IBW=83%), height 85 cm (<3rd percentile). Groin lymph nodes enlargement was found in various size and non tender. Examination on the extremities revealed deformity, swelling, and pain on palpation with limited range of movement of the left lower leg. No signs of fracture were found. There was BCG scar. Other findings were normal.

Laboratory examinations revealed hemoglobin 9.8 g/dL, white blood cells 15,600/ μ L, platelets 577,000/ μ L. Erythrocyte sedimentation rate was 12 mm/hour. Serum electrolyte revealed sodium 137 mEq/L, potassium 4.8 mEq/L, calcium 9.3 mg/dL, chloride 94 mmol/L. Blood urea nitrogen 10.8 mg/dL, creatinin serum 0.3 mg/dL, ALT 145 U/L, AST 161 U/L, alkali phosphatase 639 U/L, albumin 3.7 g/dL. No microorganism was found on blood culture. TB dot was negative. Tuberculin skin test was negative.

Chest x-ray revealed infiltrate on the upper part of right hillus. Radiological examination of the pelvis revealed lytic lesion in right iliac bone. Cruris x-ray revealed destruction of the diaphyse and periosteal retraction of left tibia, suggested osteomyelities. Thoraco-lumbal x-ray revealed lytic lesion of the right iliac and ischia, suggested chronic osteomyelitis. See **Figure 1**.

Tuberculosis score was 6. Based on history, physical, laboratory, radiological and tuberculosis score findings, tuberculous osteomyelitis was suspected. Histopathological examination on FNAB specimen from left tibia revealed histiocytes figuring epitheloid, and multinucleated giant cells; caseous necrosis and lymphoid cell was not found; these findings suggested to be tuberculous osteomyelitis. No sign of malignancies was noted. Anti-tuberculosis drugs, i.e., isoniazide 100 mg, rifampicin 100 mg, pirazinamide 150 mg, and streptomycin 150 mg were administered daily.

On the 4th day of admission, otitis externa developed. Framycetin sulphate, gramicidin, and

dexamethasone as ear drop were administered. Acid-fast-bacilli examinations of gastric aspirates for 3 consecutive days were negative.

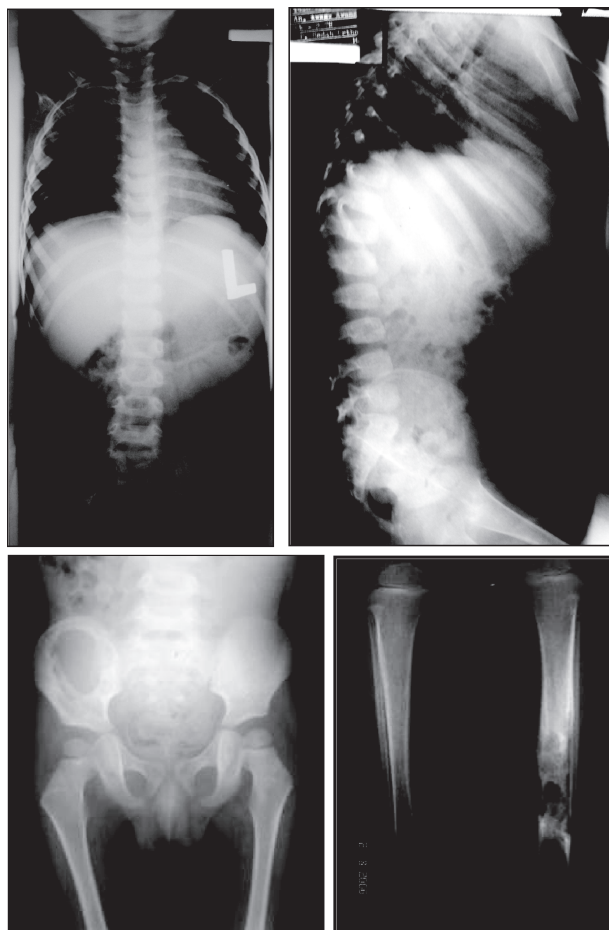


Figure 1. Radiographic examinations revealed infiltrate on the upper part of right hillus, lytic lesion in right iliac wing, destruction of the diaphyse and periosteal retraction of left tibia.

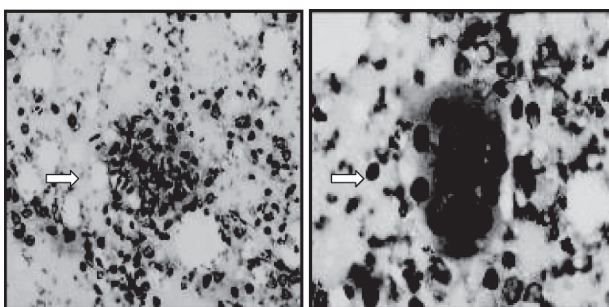


Figure 2. Cytologic examinations of FNAB, revealed epitheloid, and multinucleated giant cells.

In the fourth weeks of anti TB drugs, the diagnosis of tuberculous osteomyelitis was re-evaluated, because of no clinical improvement. New pain on the right knee developed. The possibility of malignancy was suspected. Bone marrow aspiration was planned but the parents refused. Radiological examination revealed lytic lesion on the right costae VIII. Re-anamnesis revealed history of scalp itching, otorrhea, and mouth lesions. Hystiocytosis was suspected. Scalp and external ear canal scraping was planned, unfortunately no scalp itching found during hospitalization, and otitis externa has been recovered.

From the cytology point of view, the diagnosis of tuberculosis could not be excluded, because epithelioid cells were found while the diagnosis of histiocytosis has not yet been established, since no Langerhans' cell was found (Figure 2).

On day 25 of hospitalization, skull x-ray was performed that revealed multiple lytic lesions on the calvarias, no soft tissue swelling was noted, suggested histiocytosis. Knee radiograph in anteroposterior and lateral view revealed multiple lytic lesions accompanied by cortex destruction on the metadiaphyse region of the right femur. See Figure 3.

On day 32, deformity of the distal tibia, pus, and necrotic tissue were evident. Pathology anatomical examinations taken by open biopsy on this site revealed abundant proliferation of histiocytes with oval-nucleus figuring linear groove and foamy cytoplasm, multinucleated giant cells (Langerhans' cell), lymphocytes, and eosinophils, disclosed the diagnosis of Langerhans' cell histiocytosis (Figure 4). PCR examination as well as tissue culture for *M. tuberculosis* and non-specific agents showed negative results. Anti tuberculosis drugs were discontinued and chemotherapy was administrated according to histiocytosis protocol therapy.

History of polyuria and polydipsia was not found. Osmolality measurement could not be performed in our hospital. Thyroid stimulating hormone (TSH) was 0.2 $\mu\text{IU/mL}$ (0.4-7.0 $\mu\text{IU/mL}$), T3 total was 0.7 ng/mL (0.6-2.0 ng/mL), and T4 total was 10.5 $\mu\text{g/mL}$ (4.6-11 $\mu\text{g/mL}$).

On day 56 of hospitalization, curettage and bone graft of left tibia and right femur were performed. Pathology anatomical examination of curettage specimens revealed Langerhans' Cell Histiocytosis

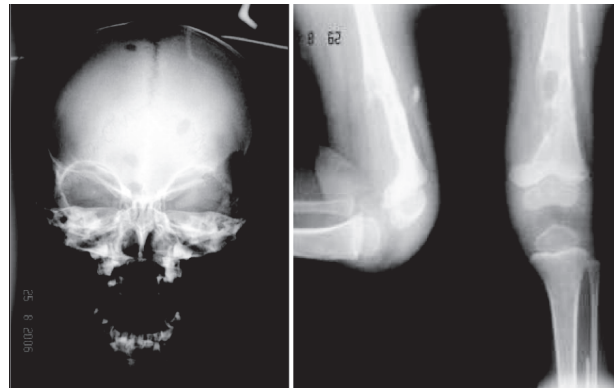


Figure 3. Skull x-photo multiple lytic lesions on the calvarias and multiple lytic lesions accompanied with cortex destruction on the metadiaphyse region of the right femur

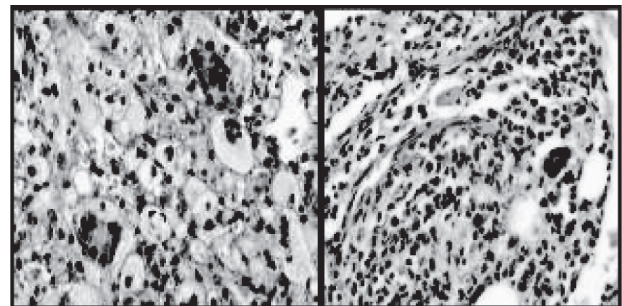


Figure 4. Histopathology examinations of the open biopsy specimen revealed Langerhans' Cell Histiocytosis

(proliferation of histiocytes with oval-nuclei that figuring linear groove and foamy cytoplasm, eosinophil, and multinucleated giant cell).

On October 7, 2006, the initial phase of chemotherapy had been completed and the patient was treated in outpatient clinic.

On January 2007, the clinical improvement was achieved. On the 20th week of therapy, radiographic evaluation of skull revealed no bone destruction. There were sclerotic lesions on the left tibia and right femur with normal trabeculations, subcondral bone layer, and joint surface; no soft tissue swelling was evident on the lower extremities suggested healing process of histiocytosis X.

Discussion

Osteomyelitis should be considered in any child with nonuse or decrease use of the extremities. Plain-film radiographs may reveal osteolysis, periosteal reaction and sequester. Histopathological and microbiological examinations of bone are the gold standard for diagnosing osteomyelitis.¹

In our case, the symptoms of osteomyelitis occurred since 6 months. Bone lesion was present with limp and painful gait. The systemic symptoms, such as fever, night sweat, and weight loss were found. Radiographic examinations revealed lytic lesion on the right iliac and ischial bones, bone destruction with periosteal retraction on the diaphyse of the left tibia and metaphyse of the right femur. Chronic osteomyelitis was more likely. Because the clinical manifestation in our patient is systemic and subtle in nature, tuberculous osteomyelitis was suspected.

Tuberculosis score was 6. Acid-fast bacilli examinations for 3 consecutive days were negative. FNAB revealed histiocytes figuring epitheloid and multinucleated giant cells; caseous necrosis and lymphoid cell were not found; suggested tuberculous osteomyelitis. The diagnosis of Tuberculous Osteomyelitis was then established.

Response to anti tuberculosis therapy should be evaluated in 2 months. In our case, after having been treated with antituberculosis for 12 weeks no clinical improvement was evident. New bone lesion was found in right femur. The diagnosis of Tuberculous Osteomyelitis was then re-evaluated. Radiographs review and skull photo revealed multiple lytic lesions. Re-anamnesis revealed history of scalp itching, otorrhea, and mouth lesions. The diagnosis of Histiocytosis was suspected.

Based on radiological, histopathological, and PCR findings, the diagnosis of tuberculous osteomyelitis was excluded, and Langerhan's cell histiocytosis (LCH) was established.

Biopsy was the key to diagnosis of LCH.¹¹ The most common histological picture of bone lesions is infiltration of histiocytes with plump, oval or reniform nuclei in diffuse eosinophil cytoplasm. In classical cases there are secondary infiltration of eosinophil which may congregate to form the so-called eosinophil micro-abscess.¹² The hallmark of these lesions is the presence of Langerhans' cells by light microscope.^{11,13}

The key pathologic finding in LCH is the presence of Birbeck granules in cell of the lesion, detected by electron microscopy. However the significance of this diagnostic structure is unknown.¹³

LCH replaces the term histiocytosis X as well as the eosinophilic granuloma syndrome, Hand-Schüller-Christian disease, and Letterer-Siwe disease, which had been included under the term histiocytosis X. The disease may present at any time from infancy to old age, but the peak incidence is 1 to 3 years old.¹⁴

The presenting symptoms of the disease were variable and non-specific. The clinical hallmark of LCH has been the presence of lytic bone lesions, but clinical manifestation may be variable. Formerly, when either single or multiple bone lesions alone were present, the disease was referred to as eosinophilic granuloma. When granulomas were more widespread, causing bone lesions, diabetes insipidus (by involvement of the pituitary), and exophthalmia (by the presence of retro-orbital granulomas), the disease was termed Hand-Schüller-Christian disease. Finally, the disseminated form of LCH was previously called Letterer-Siwe disease. This presentation is more commonly seen in infants and children younger than 2 years and is characterized by wasting, hepatosplenomegaly, generalized lymphadenopathy, anemia, and sometime pancytopenia.¹⁴ Primary hypothyroidism due to thyroid gland infiltration may also occur.¹⁵ Among these three types, there are many intermediate forms and one form may change into another.¹¹

In our case, there was history of scalp itch. Hepatosplenomegaly, exophthalmia, pancytopenia, hypothyroid, and diabetes insipidus were not found. The histiocytosis in this patient was classified as eosinophylic granuloma.

In LCH, skin involvement is most common in babies. Brownish-red maculopapules, very similar to seborrheic eczema are seen, distributed most often on the scalp (resembling severe cradle cap), post auricular areas, and midline of the trunk, axillary and groin creases and nappy area. Persistently discharging ears are a common presenting symptom and reflect involvement of skin within the ear canal or occasionally extension of bony disease into the ear canal. Super-infection is often present.¹⁶

The clinical manifestations that mimic osteomyelitis caused missed in diagnosis. The symptoms of bone swelling, pain, fever, weight loss, lymph node

enlargement, fulfill tuberculosis score. Evaluation of tuberculosis score is important in patient newly treated with anti tuberculosis drugs. If there is no improvement, another disease should be considered. Radiological review revealed multiple lytic lesions. Based on clinical manifestation, radiology and histopathology examination from bone biopsy, the diagnosis of Langerhans' Cell Histiocytosis was established. Cytology and histopathology examinations should be interpreted in conjunction with clinical manifestations, laboratory and radiological findings. Curettage and bone graft was performed. Chemotherapy was administrated. Clinical improvement occurred. The prognosis was good, because the patient was at the age of 2 years old and there was no organ involvement.

References

1. Carek PJ, Dickerson LM, Sack JL. Diagnosis and management of osteomyelitis. *Am Fam Phisician* 2001; 63:2413-20.
2. Stull MA, Kransdorf MJ, Devaney KO. Langerhans cell histiocytosis of bone. *Radiographic* 1992;12:801-23.
3. Unpublished data. Hematology-Oncology division, Department of Child Health, Medical Faculty of Airlangga University, Dr. Soetomo Hospital Surabaya.
4. Arush MWB, Pearce JM. Assessment of bone lesions. In: Hochberg Z, editor. *Practical algorithms in pediatric hematology and oncology*. Basel: Karger; 2003. p. 84-5.
5. Lau AS, Uba A, Lehman D. Bone and joint infections. In: Rudolph A, Kamei R, Overby KJ, editors. *Rudolph's fundamentals of pediatrics*. 3rd edition. New York: McGraw-Hill; 2002. p. 364-70.
6. Churchill RB. Infections of bones, joints, and soft tissues. In: Rudolph CD, Rudolph AM, Hostetter MK, Lister G, Siegel NJ, editors. *Rudolph's pediatrics*. 21st edition. New York: McGraw Hill; 2003. p. 904-9.
7. Barr DGD. Disorder of the skeleton. In: Hendrickse RG, Barr DGD, Matthews TS, editors. *Pediatrics in the tropics*. Oxford: Blackwell Scientific Publications; 1991. p. 410-33.
8. American Thoracic Society. Diagnostic standards and classification of tuberculosis in adults and children. *Am J Respir Crit Care Med* 2000;161:1376-95.
9. West DC. Bone tumor. In: Rudolph A, Kamei R, Overby KJ, editors. *Rudolph's fundamentals of pediatrics*. 3rd edition. New York: McGraw-Hill; 2002. p. 585-9.
10. Senac MO, Isaacs H, Gwinn JL. Primary lesions of bone in the 1st decade of life: retrospective survey of biopsy results. *Radiology* 1986;160:491-5.
11. Sessa S, Sommelet D, Lascombes P, Prevot J. Treatment of langerhans-cell histiocytosis in children. Experience at the children's hospital of Nancy. *J Bone Joint Surg Am* 1994;76:1513-25.
12. Cheyne C. Histiocytosis X. *J Bone Joint Surg* 1971; 53B:366-82.
13. Akerman M. Bone. In: Orell SR, Sterrett GF, Whitaker D, editors. *Fine needle aspiration cytology*. 4th edition. Livingstone: Elsevier Churchill; 2005. p. 433-44.
14. Ladisch S, Jafe ES. Histiocytoses. In: Pizzo PA, Poplack DG, editors. *Principles and practice of pediatric oncology*. 4th edition. Philadelphia: Lippincott Williams & Wilkins; 2002. p. 733-50.
15. Ladisch S. Histiocytosis syndromes in childhood. In: Behrman RE, Kliegman RM, Jenson HB, editors. *Nelson Textbook of Pediatrics*. 17th edition. Philadelphia: Saunders; 2004. p. 1727-30.
16. Craze JL, Pritchard J. Langerhans' cell histiocytosis: a case history. *Ann Onc* 1996;7:89-94.