

## Optic nerve sheath diameter and severity of central nervous infection

Anggun Puspita Dewi, Dzulfikar Djalil Lukmanul Hakim, Sri Endah Rahayuningsih,  
Nelly Amalia Risan, Raden Reni Ghrahani, Riyadi Adrizain

### Abstract

**Background** Central nervous system (CNS) infection affects the brain, and can cause cerebral edema, increased intracranial pressure (ICP), cerebral herniation, and death. Measurement of the optic nerve sheath diameter (ONSD) by ultrasound is a new, non-invasive examination to predict ICP, with high sensitivity and specificity.

**Objective** To analyze for a possible association between ONSD measured by ultrasonographic examination and severity of CNS infection.

**Methods** This cross-sectional study was performed in the Pediatric Department of Hasan Sadikin Hospital, Bandung, West Java. Subjects were chosen by consecutive sampling. We measured ONSD, examined clinical manifestations, as well as performed a cerebrospinal fluid (CSF) study and imaging of CNS infection. Data analysis was done by paired T-test and one-way ANOVA, followed by Tukey test on significant variables.

**Results** Subjects consisted of 32 children with CNS infection. The most common clinical symptoms were fever, decreased consciousness, and nuchal rigidity. Bivariate analysis revealed strong positive associations between ONSD and Glasgow Coma Scale (GCS), increased protein levels in CSF, and type of CNS infection.

**Conclusion** Larger ONSD is significantly associated with lower GCS, increases CSF protein, and particular CNS infections. The ONSD is also associated with meningitis tuberculosis grade III, with a higher mean ONSD of both eyes compares to other CNS infections. Hence, the higher the ONSD, the more severe the degree of CNS infection. [Paediatr Indones. 2023;63:411-7; DOI: <https://doi.org/10.14238/pi63.5.2023.411-7> ].

**Keywords:** cerebral edema; CNS infection; increased ICP; ONSD

Central nervous system (CNS) infections occur in the lining of the brain, brain tissue, or both, and are an important cause of morbidity and mortality in children.<sup>1,2</sup> According to *World Health Organization* (WHO), the annual mortality rate of CNS infections was 422,900 in 2020, in which encephalitis contributed to 143,500 cases. A study in United Kingdom in year 2015-2019, reported that 37.8% of deaths were caused by CNS infections and 22.2% of deaths were caused by encephalitis from 2015 to 2019.<sup>1,2</sup>

Complications of CNS infection usually found in children are cerebral edema, which can lead to increased intracranial pressure (ICP), brain herniation, and death.<sup>3,4</sup> Increased ICP can be diagnosed through the assessment of clinical manifestations, imaging examinations, and measurement of intraventricular pressure. Blood tests are performed on patients suspected of having increased ICP due to infection and electrolyte imbalance, in addition to CSF examination and other investigations, including imaging technique,

From the Department of Child Health, Universitas Padjadjaran Medical School/Dr. Hasan Sadikin Hospital, Bandung, West Java, Indonesia.

**Corresponding author:** Anggun Puspita Dewi. Department of Child Health, Universitas Padjadjaran Medical School/Dr. Hasan Sadikin Hospital. Gedung Kenanga Lantai 3, Jl. Pasteur No.38, Bandung, 40161. Email: [Anggunpdewi90@gmail.com](mailto:Anggunpdewi90@gmail.com).

Submitted November 14, 2022. Accepted November 13, 2023.

such as computer tomography (CT)-scan and magnetic resonance imaging (MRI). Imaging findings in patient with increased ICP include cisterna basalis compression, midline shift, meningeal enhancement, tuberculoma, infarction, ischemia, and hydrocephalus, which indicate signs of cerebral edema. In pediatric patients with CNS infection who are critically ill, a rapid diagnostic tool is needed for early detection of increased ICP. However, these procedures commonly require invasive techniques which are difficult to perform in an emergency setting. Several novel examinations are quick, easy to perform, and non-invasive. One such method is ultrasound examination of the optic nerve sheath diameter (ONSD) with a periorbital approach, which has predictive value in detecting changes in ICP. It can be performed by any physician, not just radiologists, and has high sensitivity and specificity as a diagnostic tool. The ONSD measurement by ultrasound yielded higher sensitivity and specificity than ONSD measurement by CT-scan or MRI. Moreover, the threshold for ultrasonographic ONSD measurement is  $>4.0$  mm in infants,  $>4.71$  mm in children aged 1–10 years, and  $>5.43$  mm in adolescents aged  $>10$  years for increased ICP, with 100% sensitivity and 60–66.7% specificity, with 85% of patients showing elevated ICP.<sup>4,5</sup>

A study of adult population with tuberculous meningitis at the time of ER admission reported that large ONSD was strongly associated with disease severity, abnormal brain imaging results, and high mortality rate.<sup>6</sup> The ONSD examination by ultrasound is potentially becoming a useful bedside diagnostic tool in neurological emergency cases, since it is non-invasive and affordable for predicting increased ICP.<sup>6,7</sup> Unfortunately, study on this topic is still lacking, particularly in pediatric populations. Thus, the aim of this study was to evaluate for an association between ultrasonographic ONSD examination and severity of central nervous infection.

## Methods

This cross-sectional study was conducted in the emergency room and Pediatric Ward of Department of Child Health, Faculty of Medicine of Universitas Padjadjaran/Dr. Hasan Sadikin Central General Hospital, Bandung, West Java, from August to

October 2022. Consecutive sampling was used to recruit a minimum required sample size of 32 patients. The inclusion criteria were patients aged 2 to  $<18$  years; patients admitted to the emergency room with CNS infection; and patients whose parents provided informed consent to participate in the study. The exclusion criteria were patients with ocular trauma or eye pathology, such as: exophthalmos, periorbital mass, infection of conjunctiva, or glaucoma, as well as patients who had received osmotherapy to treat increased ICP, patients with open fontanelles, and patients with decreased consciousness due to metabolic disturbances and shock (blood glucose  $<50$ mg/dL, sodium  $<125$ mEq/L). The study was approved by the Health Research Ethics Committee of the Faculty of Medicine, Universitas Padjadjaran/Dr. Hasan Sadikin Central General Hospital, Bandung, West Java.

All study subjects underwent ultrasound examination performed by Radiology Department resident doctors trained in advanced ultrasonography techniques. Examination results were validated and interpreted by a radiology consultant. The ultrasonography tool used was a PHILIPS Lumify with *High-Frequency Linear L12-4* broadband linear array transducer. Data were recorded in a study form developed for data entry into Microsoft Excel, in which data cleaning (verification and coding) was carried out for analysis purposes. Data analysis was carried out in accordance with research objectives and hypotheses using *SPSS for Windows version 22* software. Descriptive analysis was performed by presenting statistical measures of number and percentage, while numerical data was normalized using Shapiro-Wilks analysis. Normally distributed data were presented in mean, while non-normally distributed data were presented in median and range. Relationships between two groups of variables were analyzed by paired T-test, while the relationships of more than two groups of variables were analyzed by one-way ANOVA test. Results with P values  $<0.05$  were considered to be statistically significant.

## Results

There were 32 subjects who fulfilled the inclusion criteria. Characteristics of subjects are presented

in **Table 1**, including patient, gender, age, chief complaint, level of consciousness (GCS), CSF examination, CT-scan examination, and grouping of diagnoses. Subjects' median age was 7.8 years, and there were more males than females. The most common clinical symptoms were fever, decreased consciousness, and nuchal rigidity. The ONSD on both eyes are presented in **Figure 1**.

Paired T-test revealed no significant difference in ONSD ocular dextra and ONSD ocular sinistra (**Table 2**). Shapiro-Wilks test of the two groups showed that the data were normally distributed. There was no significant difference in right and left ONSD between males and females ( $P > 0.05$ ). Meanwhile, there was a significant association between increase in right as well as left ONSD with decreasing level of consciousness, as measured by GCS ( $P = 0.038$  and  $P = 0.008$ , respectively). Likewise, increased CSF protein was also significantly associated with larger right ( $P = 0.033$ ) and left ( $P = 0.026$ ) ONSD. The distribution of ONSD-ODS values based on CT-scan examination results did not show any differences ( $P > 0.05$ ) (**Table 4**).

In addition, higher ONSD were significantly associated with the tuberculous meningitis diagnosis ( $P < 0.05$ ), as presented in **Table 4**. Regarding the type of CNS infection, the results of the analysis showed that there were differences in the mean between each CNS infection group (encephalitis, bacterial meningitis, tuberculosis meningitis grades 1, 2, 3). For variables with a P value  $< 0.05$ , further analysis was carried out using the Tukey test, with the results showing that there was a difference in mean ONSD-ODS in grade III TB meningitis patients with ONSD-ODS in other CNS infection groups. Subjects with tuberculous meningitis grade III had the highest mean ONSD, namely, 6.14 (SD 0.97) in ONSD(ONSD-OD) and 6.10 (SD 0.75) in ONSD ocular sinistra (ONSD-OS), as shown in **Table 4**. Bivariate analysis showed a strong positive association between ONSD and GCS, ONSD and increased CSF protein levels, as well as ONSD and CNS infection, with the mean ONSD in patients with tuberculous meningitis grade 3 being higher than other CNS infections.

**Table 1.** Characteristics of subjects

Characteristics	(N=32)
Mean age (SD), years	7.8 (0.49)
Gender, n	
Male	19
Female	13
Symptoms	
Decreased consciousness	32
Seizure	4
Fever	32
Headache	3
CN paralysis	2
Vomiting	1
Nuchal rigidity	28
Level of consciousness (GCS)	
Somnolence (13-14)	17
Stupor (8-12)	13
Coma (<8)	2
CSF	
Normal protein <40 mg/dL	7
Increased protein >40 mg/dL	25
CT-scan results	
Non-hydrocephalus	16
Communicating hydrocephalus	8
Non-communicating hydrocephalus	8
Diagnosis	
Tuberculous meningitis grade 2	10
Tuberculous meningitis grade 3	8
Bacterial meningitis	5
Encephalitis	9

\*based on paired T-test

**Table 2.** Analysis of mean left (oculus sinistra/OS) and right (oculus dextra/OD) ONSD

Variables	Mean ONSD (SD)	Range	P value
OD	5.16 (0.82)	4.02-7.5	0.784
OS	5.14 (0.76)	4.05-7.08	

\*paired T-test; OD=ocular dextra; OS=ocular sinistra

**Table 3.** Analysis of right and left ONSD according to age

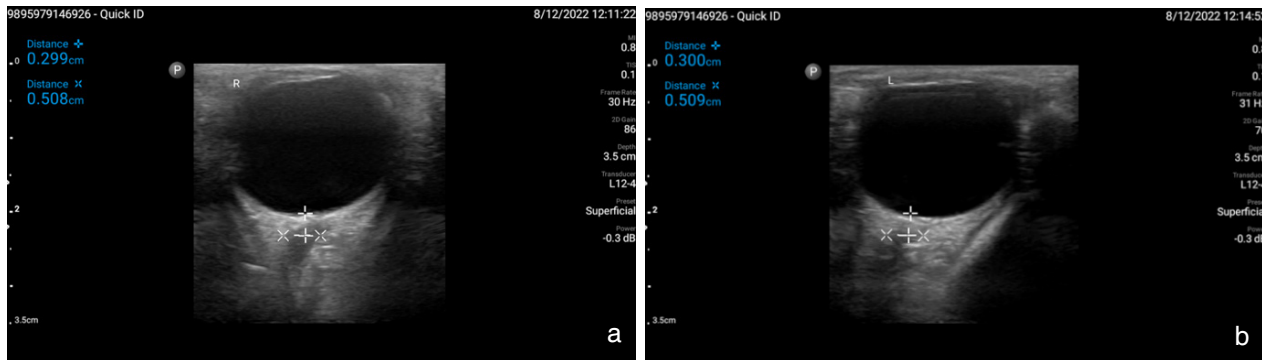
Age	Right ONSD	Left ONSD
2-<18 years	r = 0.052	P=0.778
2-<18 years	r =0.147	P=0.421

\*Pearson's test

**Table 4.** Analysis of right and left ONSD with variables

Variables	(N=32)	Mean ONSD OD (SD)	P value	Mean ONSD OS (SD)	P value
Gender					
Male	19	5.23 (0.94)	0.314	5.17 (0.85)	0.542
Female	13	5.05 (0.60)		5.11 (0.64)	
Level of consciousness (GCS)					
Somnolence (13–14)	17	4.83 (0.46)	0.038*	4.78 (0.46)	0.008**
Stupor (8–12)	13	5.50 (1.02)		5.52 (0.87)	
Coma (<8)	2	5.79 (0.78)		5.84 (0.54)	
CSF					
Normal protein <40 mg/dL	7	4.59 (0.29)	0.033*	4.59 (0.25)	0.026*
Increased protein >40 mg/dL	25	5.32 (0.85)		5.30 (0.78)	
CT-scan					
Non-hydrocephalus	16	4.94 (0.68)	0.086	5.34 (0.65)	0.354
Communicating hydrocephalus	8	5.05 (0.62)		5.02 (0.64)	
Non-communicating hydrocephalus	8	5.70 (1.06)		5.49 (1.09)	
Diagnosis					
Bacterial meningitis	5	4.68 (0.24)	0.000**	4.73 (0.24)	0.000**
Encephalitis	9	4.60 (0.81)		4.52 (0.25)	
Tuberculous meningitis grade 2	10	5.11 (0.32)		5.15 (0.43)	
Tuberculous meningitis grade 3	8	6.14 (0.97)		6.10 (0.75)	

\*T-test for 2 variables, and \*\*one-way ANOVA test for >2 variables



**Figure 1.** Periorbital ultrasound of left and right eyes with increased ICP  
a. ONSD Ocular Dextra (ONSD OD), b. ONSD Ocular Sinistra (ONSD OS)

## Discussion

Analysis of age and gender data did not show any relationship between ONSD and age as well as gender. Because in this study age was taken as an inclusion criterion, namely children aged > 2 years with fontanelles already closed. Normal ONSD cut-off points were <4mm in children <1 year, <4.5mm in children > 1 year, and <5 mm in children >4 years.<sup>8</sup> They study included children aged 2 to <18 years, with the consideration that fontanelles are expected to have closed at the age of 24 months. The ONSD should not be applied to pediatric patients with an

open anterior fontanel since the measured diameter and ICP cannot be used as true values and were shown to be biased. Furthermore, the correlation between ONSD and ICP was also better in children with closed anterior fontanel compared to children with open anterior fontanel ( $r=0.7$  vs.  $r=0.56$ , respectively;  $P<0.001$ ), suggesting that the ONSD technique is less useful in patients with an open anterior fontanel.<sup>9,10</sup> Although we found no relationship between ONSD and gender, a previous study reported that the incidence of infection, especially meningitis, was more common in male children.<sup>11</sup>

Paired T-test revealed no significant difference

in ONSD OD and OS values. Similarly, a previous study noted no difference between ONSD OD and OS in adult patients ( $P=0.12$ ). We performed this analysis to ensure that there was no localized brain abnormality, such as in encephalitis, increase in ONSD may be unilateral due to the location of the lesion.<sup>10,12</sup>

The ONSD and GCS score had a significant negative association. As presented in **Table 4**, lower GCS was associated with higher mean right ONSD and left ONSD. ONSD was highest in comatose patients compared to those with somnolence or stupor. This findings are similar with a study which also reported that ONSD was greater in coma-conscious patients compared to other decreased consciousness patients,<sup>6</sup> as well as another study that reported a correlation between ONSD and GCS, and suggested that ONSD measurement could be a predictive factor in the decision-making process in pediatric patients with decreased consciousness, depending on the disease severity and duration of infection resulting in severe brain tissue damage, as well as fluid accumulation in the non-communicating hydrocephalus that can cause a more severe disturbance of consciousness.<sup>13</sup>

Various characteristics were assessed by CSF analysis, including fluid color, cell count, glucose, leukocytes, and protein. The presence or absence of increased protein was assessed. The increase in protein is caused by two factors. First, the permeability of the blood-brain barrier increases so that higher molecular weight proteins can easily enter the CSF. Second, these higher molecular weight proteins may enter the CSF synthesis area in the cerebrospinal tract through inflammatory processes or a large number of proinflammatory cells. Normal protein levels in CSF are less than 40 mg/dL, but if inflammation or infection occurs then protein excretion will be larger in size, and more from the choroid plexus and the permeability of the blood-brain barrier is damaged, then CSF protein results will be found which tend to increase  $>40$ mg/dL along with the duration of the disease until before receiving therapy. Protein levels in newborns are significantly higher than in older children and adults, with normal levels averaging 90 to 170 mg/dL. Very high CSF protein levels (more than 1 g/dL) indicate a CSF spinal block or obstruction, especially in infectious conditions. In our study, ONSD was significantly higher in patients with CSF

protein levels  $>40$ mg/dL ( $P=0.033$  and  $P=0.026$  for right and left ONSD, respectively).<sup>14</sup>

The classic neuroradiological features of meningitis are basal meningeal elevation, hydrocephalus, granulomatous parenchyma, and infarction. Of our subjects, CT-scan revealed that 16 patients had non-hydrocephalus, 8 patients had communicating hydrocephalus, and 8 patients had non-communicating hydrocephalus. However, there was no significant difference in ONSD among the CT-scan results. The proportion of non-hydrocephalus was higher than hydrocephalus.<sup>10</sup> Central nervous system (CNS) infections may manifest as meningitis, encephalitis, meningoencephalitis, arachnoiditis, or ventriculitis. Tuberculous meningitis is the most common form of infection presenting as a serious neurological emergency, especially in developing countries.<sup>9</sup> A study on patients with CNS infections in developing countries from 2000 to 2019 found that the most common CNS infections in children were meningitis (80.7%), followed by cerebral abscess (12.1%), and encephalitis (6.5%).<sup>15</sup> In agreement with that finding, we noted 23 (73.6%) cases of meningitis from 32 cases of CNS infection, with grade 2 tuberculous meningitis in 10 patients (31.3%), encephalitis in 9 patients (28.1%), tuberculous meningitis III in 8 patients (25.0%), and bacterial meningitis in 5 patients (15.6%). In a previous study of adult subjects, prospective data showed that an ONSD of  $>5$ mm in patients with tuberculous meningitis correlated well with ICP  $>20$  cm H<sub>2</sub>O.<sup>15</sup> Moreover, in our study, the group with a diagnosis of grade III tuberculous meningitis had higher mean ONSD (6.14 mm in ONSD OD and 6.10 mm in ONSD OS). Tuberculous meningitis is a subacute disease with symptoms that can persist for weeks before a diagnosis is made. This is supported by the theory that rupture of tubercles into the subarachnoid space in tuberculous meningitis causes a hypersensitivity response that results in aggravating the condition of ICP and hydrocephalus. Tuberculous meningitis may be symptomatic for weeks before the proper diagnosis is made. CNS infections that last longer than other groups of CNS infections contribute to the occurrence of more severe brain abnormalities than other CNS infections.<sup>14,15</sup>

The ONSD ultrasonographic examination has the potential of becoming a very sensitive screening

tool for elevated ICP in children with CNS infections. Examination of all study subjects was carried out by two examiners, in which each patient was examined, followed by validation and interpretation by a radiology consultant to avoid potential observer and measurement bias.

In conclusion, ONSD is significantly higher in patients with more severe CNS infection. The ONSD is also significantly higher in patients with GCS coma status, CSF with protein >40 mg/dL, and grade III tuberculous meningitis. Mean ONSD is significantly higher in grade III tuberculous meningitis than in other CNS infections.

### Conflict of interest

None to declared.

### Acknowledgment

The authors would like to thank Dr. Harry Galuh Nugraha dr, Sp.Rad for validating and interpreting the periorbital ultrasound results.

### Funding acknowledgment

The authors received no specific grants from any funding agency in the public, commercial, or not-for-profit sector.

### References

1. Stead GA, Cresswell FV, Jjunju S, Oanh PKN, Thwaites GE, Donovan J. The role of optic nerve sheath diameter ultrasound in brain infection. *eNeurologicalSci*. 2021;23:100330. DOI: <https://doi.org/10.1016/j.ensci.2021.100330>.
2. Ropper A, Samuels M. Adams and Victor's Principles of Neurology. 9<sup>th</sup> ed. New York: McGraw-Hill; 2009. p. 339-61. ISBN: 9780071499927.
3. Dando SJ, Mackay-Sim A, Norton R, Currie BJ, St. John JA, Ekberg JAK, et al. Pathogens penetrating the central nervous system: infection pathways and the cellular and molecular mechanisms of invasion. *Clin Microbiol Rev [Internet]*. [cited 2022 Nov 10] 2014;27:691-726. DOI: <https://doi.org/10.1128/CMR.00118-13>.
4. Donovan J, Oanh PKN, Dobbs N, Phu NH, Nghia HDT, Summers D, et al; Vietnam ICU Translational Applications Laboratory (VITAL) Investigators.. Optic nerve sheath ultrasound for the detection and monitoring of raised intracranial pressure in tuberculous meningitis. *Clin Infect Dis*. 2021;73:e3536-e3544. DOI: <https://doi.org/10.1093/cid/ciaa1823>.
5. Kirkham FJ, Newton CRJC, Whitehouse W. Paediatric coma scales. *Dev Med Child Neurol*. 2008;50:267-74. DOI: <https://doi.org/10.1111/j.1469-8749.2008.02042.x>.
6. Cannata G, Pezzato S, Esposito S, Moscatelli A. Optic nerve sheath diameter ultrasound: a non-invasive approach to evaluate increased intracranial pressure in critically ill pediatric patients. *Diagnostics (Basel)*. 2022;12:767. DOI: <https://doi.org/10.3390/diagnostics12030767>.
7. Kendir Ö, Yılmaz H, Ballı HT, Gökay SS, Ünal I, Özkaya AK. Diagnostic and clinical predictive value of optic nerve sheath diameter measurement in children with increased intracranial pressure. *Erciyes Med J*. 2021;43:554-9. DOI: <https://doi.org/10.14744/etd.2021.43809>
8. Kerscher SR, Schöni D, Hurth H, Neunhoffer F, Haas-Lude K, Wolff M, et al. The relation of optic nerve sheath diameter (ONSD) and intracranial pressure (ICP) in pediatric neurosurgery practice - Part I: Correlations, age-dependency and cut-off values. *Childs Nerv Syst*. 2020;36:99-106. DOI: <https://doi.org/10.1007/s00381-019-04266-1>.
9. Selhorst JB, Chen Y. The optic nerve. *Semin Neurol*. 2009;29:29-35. DOI: <https://doi.org/10.1055/s-0028-1124020>.
10. Joukal M. Anatomy of the human visual pathway. In: Skorkovská K, ed. Homonymous visual field defects. NYC: Springer, Cham; 2017. p.1-16. DOI: [https://doi.org/10.1007/978-3-319-52284-5\\_1](https://doi.org/10.1007/978-3-319-52284-5_1).
11. Young AMH, Guilfoyle MR, Donnelly J, Scoffings D, Fernandes H, Garnett M, et al. Correlating optic nerve sheath diameter with opening intracranial pressure in pediatric traumatic brain injury. 2017;81:443-7. DOI: <https://doi.org/10.1038/pr.2016.165>.
12. Yanamandra U, Gupta A, Bhattachar SA, Yanamandra S, Das SK, Patyal S, et al. Comparison of optic nerve sheath diameter between both eyes: a bedside ultrasonography approach. *Indian J Crit Care Med*. 2018;22:150-3. DOI: [https://doi.org/10.4103/ijccm.IJCCM\\_498\\_17](https://doi.org/10.4103/ijccm.IJCCM_498_17).
13. du Toit GJ, Hurter D, Nel M. How accurate is ultrasound of the optic nerve sheath diameter performed by inexperienced operators to exclude raised intracranial pressure? *S African J Radiol*. 2015;19. DOI: <https://doi.org/10.4102/SAJR.v19i1.745>.
14. Sangani SV, Parikh S. Can sonographic measurement

- of optic nerve sheath diameter be used to detect raised intracranial pressure in patients with tuberculous meningitis? A prospective observational study. *Indian J Radiol Imaging* 2015;25:173-6. DOI: <https://doi.org/10.4103/0971-3026.155869>.
15. Gora H, Smith S, Wilson I, Preston-Thomas A, Ramsamy N, Hanson J. The epidemiology and outcomes of central nervous system infections in Far North Queensland, tropical Australia; 2000-2019. *PLoS One*. 2022;17:e0265410. DOI: <https://doi.org/10.1371/journal.pone.0265410>. eCollection 2022.
  16. Shidokar CG, Rao SM, Mutkule DP, Harde YP, Venkatesgowda PM, Mahesh MU. Optic nerve sheath diameter as a marker for evaluation and prognostication of intracranial pressure in Indian patients: an observational study. *Indian J Crit Care Med*. 2014;18:728-34. DOI: DOI: <https://doi.org/10.4103/0972-5229.144015>
  17. Siddiqui NUR, Haque A, Abbas Q, Jurair H, Salam B, Sayani R. Ultrasonographic optic nerve sheath diameter measurement for raised intracranial pressure in a tertiary care centre of a developing country. 2018;30:495-500. PMID: 30632323.