

Laurence-Moon-Bardet-Biedl syndrome: a case report

Md. Mozammel Haque¹, Kamrunnaher Shultana², Tahmina Binte Matin³,
Md. Shohidul Islam Khan¹, Abdullah Al Baki¹

L Laurence-Moon-Bardet-Beidl syndrome is a rare ciliopathic and pleiotropic human autosomal recessive genetic disorder.¹ In 1886, Laurence and Moon explained a case of a 7-year-old female with rod-cone dystrophy, hypogenitalism, mental retardation, obesity, and polydactyly. In 1920, Bardet described a 4-year-old female patient presented with rod-cone dystrophy, obesity, polydactyly (11 toes), and mental retardation.¹ Two years after Bardet's report, Biedl highlighted the complete scenario of clinical signs which includes skull abnormalities, anal atresia, mental deficiency, and gastrointestinal conflicts.¹ Since these discoveries, symptoms such as obesity, hypogonadism, retinal pigment defects, psychological hindrance, and polydactylism in several conditions as combinations, frequently in children with normal parents (cousin marriages) has been termed as Laurence-Moon-Bardet-Biedl syndrome (LMBBS).¹

Laurence-Moon-Bardet-Beidl syndrome (LMBBS) is a disorder with phenotypic and genetic heterogeneity.² The main features are obesity, polydactyly, pigmentary retinopathy, learning disabilities, various degrees of intellectual impairment, hypogonadism (in male) and renal abnormalities. Other clinical features include speech disorder, brachydactyly, developmental delay, polyuria and polydipsia, ataxia, poor coordination/clumsiness, diabetes mellitus, left ventricular hypertrophy, hepatic fibrosis and renal hypoplasia/dysplasia.² The most common feature is retinal dystrophy. The retinal appearance is quite variable, with typical retinitis pigmentosa being present in

only a minority of cases.¹ Diagnosis of the condition is important for visual prognosis and low vision management.² The patients generally have onset of symptoms within the first 10 years of life and among them the first complaint is usually poor night vision.¹ Recent reports suggest that functional and morphological abnormalities are present in up to 90% of affected patients. The renal abnormalities occur with a spectrum of activity, often causing significant morbidity and autopsy data reveals it to be the major cause of mortality.¹ The management of Laurence-Moon-Bardet-Biedl syndrome involves a multidisciplinary approach and remains a challenge for clinicians. Here, we report a case of a 7-year-old girl presented with obesity, polydactyly, retinitis pigmentosa, and mental retardation. [Paediatr Indones. 2019;59:349-52; doi: <http://dx.doi.org/10.14238/pi59.6.2019.349-52>].

Keywords: obesity; retinitis pigmentosa; polydactyly; mental retardation

From the Department of Pediatrics, 250 Bedded Hospital, Moulvibazar, Sylhet¹, Department of Pediatrics and PICU, Square Hospital Ltd, West Panthapath, Dhaka², and Department of Pediatrics, Railway General Hospital, Kamalapur, Dhaka.³

Corresponding author: Dr. Md. Mozammel Haque, Department of Pediatrics, 250 Bedded Hospital, Moulvibazar, Sylhet, Bangladesh. Telp. (88)01711148068; Email: mmhaque16rnc@yahoo.com.

Submitted January 24, 2017. Accepted November 8, 2019.

The Case

A 7-year-old girl, the firstborn of consanguineous parents, came to the pediatric outpatient department of 250 Bedded Hospital, Moulvibazar, Bangladesh, with complaints of gradual blurring of vision for the past two years and breathing difficulties during sleep for the past three years. The mother noticed that the child could not see well which was evident by repeated falls while walking on uneven surfaces and climbing stairs, groping for objects and the inability to see letters of the alphabet in books. No medical attention was sought for the vision problems because her action has been considered to be 'attention-seeking behavior' by her family members. She also suffered from breathing difficulty during sleep, blocked nasal passage, night cough, snoring, mouth breathing and recurrent sleep disturbance. No significant improvement was noted following repeated visits to local doctors. Hence, she visited the pediatric outpatient department of 250 Bedded Hospital for further evaluation and management. Her past medical history was uneventful, except that she had undergone surgical excision of an extra digit on her left hand due to infection at six months of age. Her birth, antenatal, natal and post-

natal histories were normal. She was immunized as per the expanded program of immunization (EPI) schedule. She had delayed developmental milestones as far back as her mother could remember, such as sitting at 8 months and walking at 2 years of age. Her mother had a history of one abortion at fetal gestation of four months. Her other sibling was healthy.

On general examination, the child had a puffy face, dull look and lack of attention to the surroundings. Vital signs were within normal limits. A skin survey revealed acanthosis nigricans over the neck, throat, axilla and groin. She had polydactyly (6 toes) on both feet. Her weight was 38 kg (weight-for-age >97th percentile), height was 121 cm (height-for-age 50th percentile) and body mass index (BMI) was 26 kg/m² (>95th percentile). Ophthalmoscopic examination revealed retinitis pigmentosa. She was found to be mentally retarded on neurological examination. Other systemic examinations including general examination revealed no abnormality.

Laboratory investigations including complete blood count (CBC), random blood sugar (RBS), alanine transaminase (ALT/SGPT), serum creatinin, lipid profile, free thyroxine (FT4), thyroid stimulating hormone (TSH), follicle stimulating hormone (FSH), luteinizing hormone (LH), urine routine and microscopic examination (RME) revealed normal findings. No abnormalities were seen on chest x-ray, electrocardiogram (EKG) or echocardiogram. Hepatomegaly with fatty changes in liver was detected

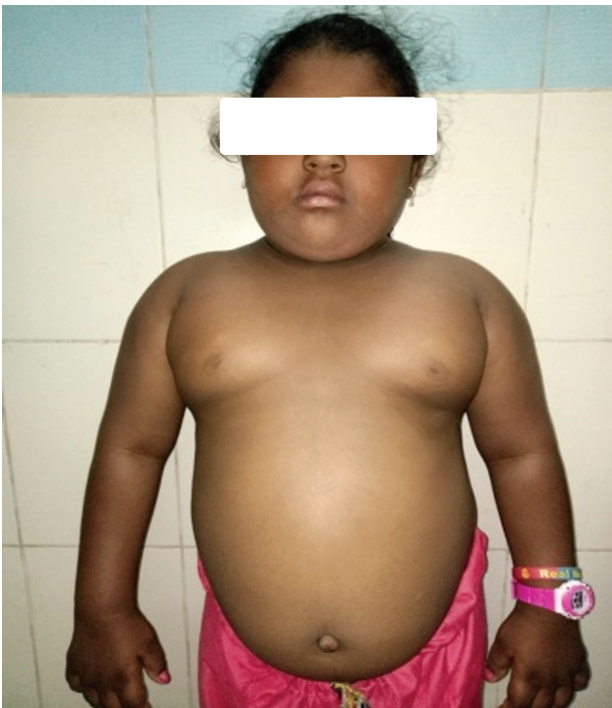

Figure 1. A 7 year-old case patient

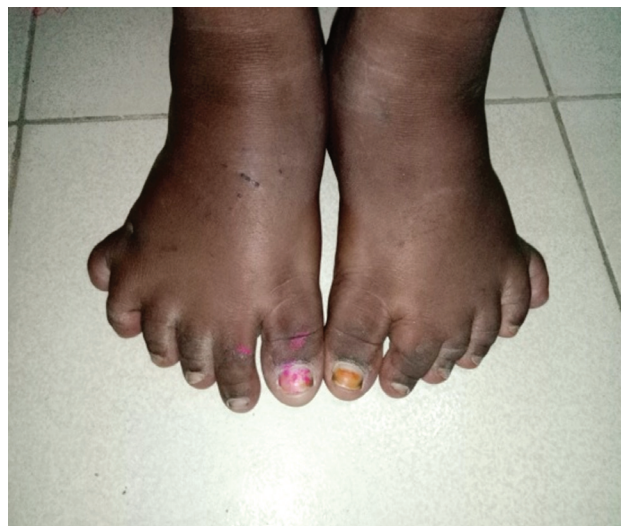

Figure 2. Polydactyly

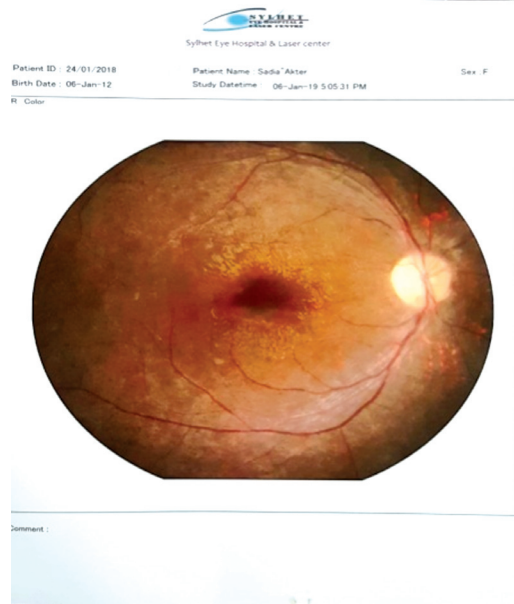


Figure 3. Retinitis pigmentosa (right eye)

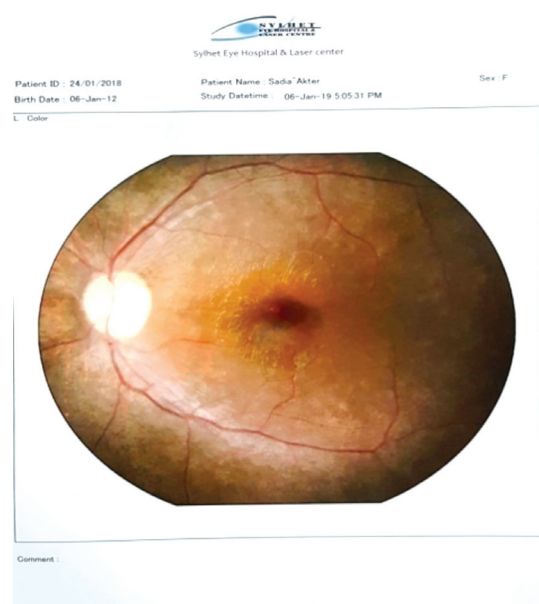


Figure 4. Retinitis pigmentosa (left eye)

by ultrasound. A nasopharynx lateral view x-ray revealed enlarged adenoids (grade-III). We diagnosed this patient to have Laurence-Moon-Bardet-Biedl syndrome on clinical grounds.

The patient was managed by a multidisciplinary approach and was regularly followed up. Proper counseling was done regarding the prognosis of the disease and the child's vision.

Discussion

Laurence-Moon-Bardet-Biedl syndrome (LMBBS) varies in its manifestation in different patients.³ Apart from the primary features of obesity, post-axial polydactyly, renal abnormalities, mental retardation, pigmentary retinopathy, and hypogenitalism, other secondary manifestations exist.³ These secondary characteristics include cardiac anomalies, neurological problems, nephrogenic diabetes insipidus, diabetes mellitus, dental anomalies, hypertension, speech disorders, behavioral problems, brachydactyly/syndactyly/clinodactyly, anosmia, lipid disorders, hepatic abnormalities and skin disorders.³ In 1999, modified diagnostic criteria were defined in a British study of 109 LMBBS patients.⁴ Patients who had at least 4 primary characteristics, or 3 primary and 2

secondary criteria, were identified as having LMBBS.⁴ Our patient had four primary features, suggesting the diagnosis of LMBBS.

Bardet-Biedl syndrome (BBS) is now the standard term that replaced the older LMBBS, after it was found that the phenotypes overlap and may be allelic.³ The prevalence of BBS was 1:160,000 in Europe and North America,⁵ although higher incidences have been reported in isolated populations of Newfoundland (1:13,000)⁶ and Kuwait (1:17,000).⁶ Diagnosis is usually not made early because the disease phenotypes are variable and slow-evolving.³ Initial loss of the rod photoreceptors is followed by early macular involvement, with the degeneration of the cone cells, causing a gradual functional loss of vision.³ Visual impairment, and probably poor school performance, are the common reasons for affected patients to seek treatment.³ The visual pathology is an indicator pointing to the diagnosis in a child with other components of the syndrome. Our patient presented with gradual blurring of her vision.

Polydactyly and obesity are well-documented features of BBS.³ Polydactyly, when present in BBS, is seen at birth. The incidence of obesity was reported to be 72 - 86% in the BBS population. Although the majority of patients have normal weight at birth, obesity usually sets in by infancy. Polydactyly in a child,

especially one with obesity, should stimulate a high index of suspicion for syndromic disorders.³

Mental retardation is a more disputed feature of BBS. Recently, objective IQ tests determined that only a minority of patients are mentally retarded. An IQ of 79 or below is found in 44% of BBS patients. The decrease in IQ level correlates with the presence of visual handicaps.⁴ This finding was similar to our case.

Hypogonadism is reportedly more frequent in BBS males than females.⁴ In BBS females, genital abnormalities encompass a wide range, including hypoplastic fallopian tubes, uterus, ovaries, partial or complete vaginal atresia, absent vaginal orifice, or absent urethral orifice.⁴ Renal failure is the major cause of morbidity and early mortality in BBS patients. A wide range of renal abnormalities has been described (chronic renal failure, parenchymal cysts, calyceal clubbing, fetal lobulation, scarring, unilateral agenesis, dysplastic kidneys, renal calculi, and vesicoureteric reflux).⁴ These features were absent in our reported case.

Bardet-Biedl syndrome (BBS) is genetically heterogeneous, with 12 BBS genes (BBS1-12) identified to date.⁷ As these BBS proteins are components of the centrosome that influences ciliary transport, this syndrome is categorized under the spectrum of ciliopathies.⁸ Genetic analysis was not carried out in our case.

References

1. Khan PA, Nishaat J, Noor S, Fatima N. Laurence-Moon-Bardet-Biedl syndrome: a rare case report in a tertiary care teaching hospital, Hyderabad, Telangana, India. *Int J Med Public Health*. 2017; 7: 68-71.
2. Andrade LJ, Andrade R, França CS, Bittencourt AV. Pigmentary retinopathy due to Bardet-Biedl syndrome: case report and literature review. *Arq Bras Oftalmol*. 2009; 72: 694-96.
3. Okoronkwo NC. A rare classical presentation of Bardet-Biedl syndrome in a three-year-old male from South East Nigeria: a case report. *Case Reports Clin Med*. 2016; 5: 243-49.
4. Ahmed SN, Shahin MA, Chowdhury R, Ahammad AM, Shazzad MN, Alam MR, *et al*. A 13-year-old female with Bardet-Biedl syndrome - a case report. *Bangladesh J Med*. 2015; 26: 31-34.
5. Green JS, Parfrey PS, Harnett JD, Farid NR, Cramer BC, Johnson G, *et al*. The cardinal manifestations of Bardet-Biedl syndrome, a form of Laurence-Moon-Biedl syndrome. *N Engl J Med*. 1989; 321: 1002-1009.
6. Farag TI, Teebi AS. High incidence of Bardet-Biedl syndrome among the Bedouin. *Clin Genet*. 1989; 36: 463-64.
7. Karaman A. Bardet-Biedl syndrome: a case report. *Dermatol Online J*. 2008; 14: 9.
8. Sulaiman, Basha SM, Kaladhar GI, Reddy SR. Laurence-Moon-Bardet-Biedl syndrome-a case report. *Asian Pac J Health Sci*. 2016; 3: 209-11.