

## Case Report

# Preoperative intralesional injection of triamcinolone acetonide for a large head and neck lymphangioma in a baby: a case report

Julius July<sup>1</sup>, Sophie Peeters<sup>2</sup>

**L**ymphangiomas (LMs) are uncommon congenital malformations of the lymphatic system, with an estimated incidence of one in 2,000 to 4,000 live births.<sup>1</sup> About half of these lesions are diagnosed at birth, and by two years of age, 90% of those with lesions have been diagnosed.<sup>2</sup> Histologically, LMs are benign lesions; however, they can pose a serious threat to the patient due to possible growth into surrounding structures, sometimes causing life-threatening complications. Treatment of large head and neck lymphangiomas in young infants is very challenging, due to the risk of surgical complications. Further challenges include the limited volume of blood loss that infants can tolerate, the lack of the option for radiotherapy or radiosurgery, and the high chance of life-threatening complications if the LM is not treated. Here, we report a case of a two-month-old baby girl presenting with a large head and neck lymphangioma. She was successfully treated with intralesional triamcinolone acetonide injections, followed by surgical resection of the lesion. [Paediatr Indones. 2017;57:274-8; doi: <http://dx.doi.org/10.14238/pi57.5.2017.274-8> ].

**Keywords:** head lymphangioma; triamcinolone acetonide; preoperative; intralesional injection

## The Case

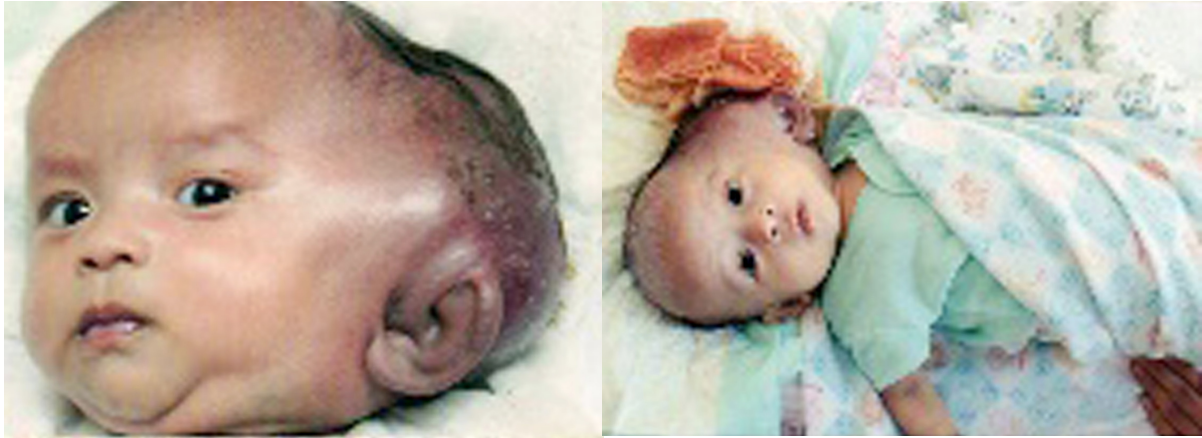The patient was a two-month-old girl presenting with a large head and neck lymphangioma on the left side (**Figure 1**). She was referred by a pediatrician for possible surgery and was rejected as a candidate for radiation therapy by a radiation oncologist. She presented with anemia and a hemoglobin level of 8.49 g/dL, likely due to the laceration on the posterolateral aspect of the mass that was actively oozing (**Figure 1**). The skin around the area was very thin and dark red. She had received multiple transfusions for anemia.

According to her mother, a dark red lump the size of a peanut was present behind the left ear at birth. The mass kept growing, despite multiple treatments. When she presented to our office, the mass was the size of an adult fist. The parents seemed quite frustrated and believed the LM to be untreatable at this point.

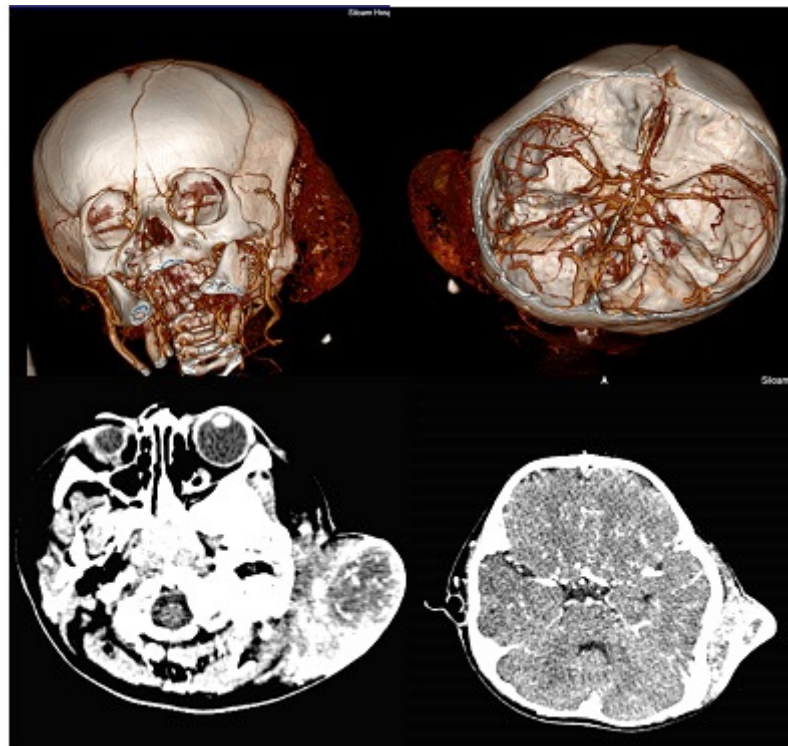
---

From the Department of Neurosurgery, Universitas Pelita Harapan Medical School, Jakarta, Indonesia.

**Reprint requests to:** Julius July, M.D., Ph.D., MHSc., IFAANS. Department of Neurosurgery, Medical Universitas Pelita Harapan Medical School. FK UPH 2nd Floor, Jl. Boulevard Jendral Sudirman Lippo Village Tangerang 15811. Phone +62-21-54210130-31. Fax +62-21-54213138. Email: [juliusjuly@yahoo.com](mailto:juliusjuly@yahoo.com).



**Figure 1.** Two-month-old girl with a large left head and neck lymphangioma and a significant lateral inferior shift of her ear. The scalp vein was engorged and there was an oozing laceration on the posterolateral aspect of the mass.



**Figure 2.** CT scan with contrast and 3D reconstruction.

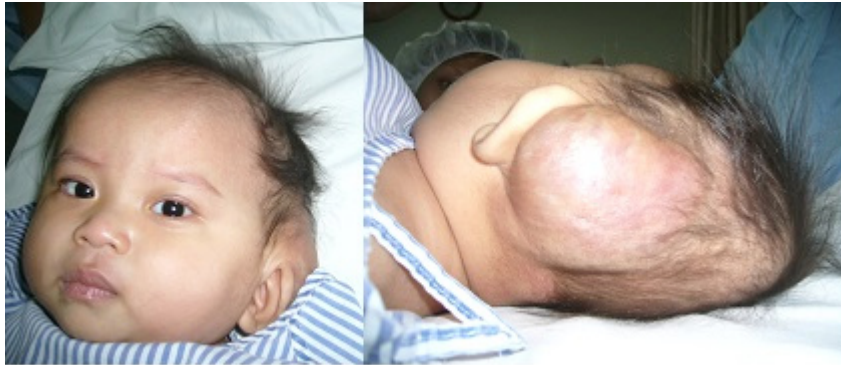Upper left: anterior view shows left retroauricular mass, 7.8 x 5.3 x 8.8 cm, highly vascularized and full of tortuous vessels. The scalp vessel was also congested, and the adjacent temporal bone had undergone remodelling. Upper right: axial view of 3D CT angiography showed no abnormal intracranial vessels. Note the remodelled temporal bone from an intracranial view. Lower left: axial cut of the contrast scan at the lower part of the lesion shows some calcifications and an intralesional hemorrhage. Lower right: the cut at the upper part of the lesion show no obvious pathology in the brain.

A CT scan showed a left retroauricular mass (Figure 2), measuring 7.8x5.3x8.8 cm, comprised of

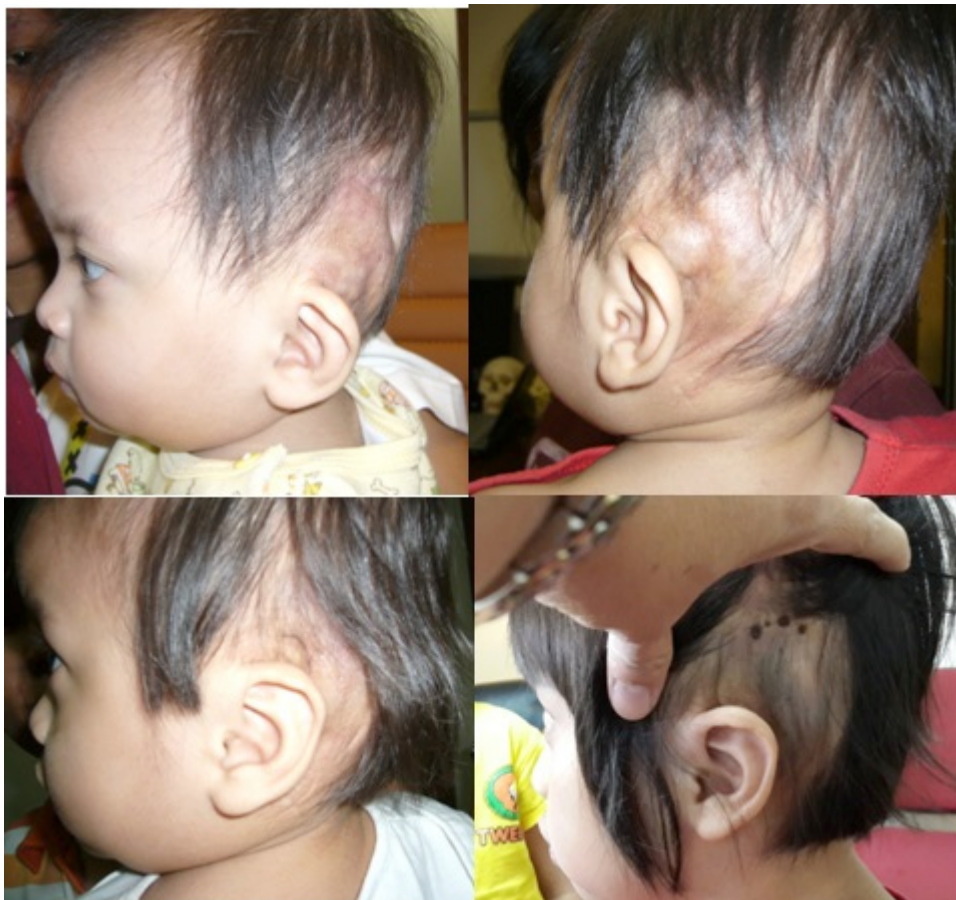tortuous internal vessels, some calcifications, and an intralesional hemorrhage. The lesion was exerting a

mass effect on the temporal bone and eroding it. The intracranial anatomy was preserved. Both clinical and radiological findings were consistent with a hemangioma or lymphangioma.

We decided to give intralesional injections of 5mg/mL triamcinolone acetonide solution for a total dose of 7.5 mg at 3-week intervals, using a 25-gauge needle. The injections were performed at random,



**Figure 3.** The lesion regressed significantly after ten sets of intralesional injections of triamcinolone acetonide. Left: Front view showing the position of left ear is almost normal. Right: side view, the mass behind the left ear regressed and the skin colour is almost normal.



**Figure 4.** Upper left: 1 month after surgery. Upper right: 6 months after surgery. Lower left: 1 year after surgery. Lower right: 3 years after surgery (age 4 years, height 92.5 cm).



at three to four different locations on the lesion per administration. The lesion regressed significantly after ten sets of injections (**Figure 3**).

Subsequently, we decided to proceed with surgical resection of the lesion. She recovered well after surgery, with no recurrence of the LM (**Figure 4**). The pathology report revealed the mass to be a lymphangioma.

## Discussion

Lymphangiomas consist of a multitude of anastomosing lymphatic channels and encapsulated cystic spaces of different sizes, filled with proteinaceous or hemorrhagic fluid.<sup>3</sup> Lymphangiomas have been classified into four histological types: lymphangioma simplex, cavernous lymphangioma, cystic hygroma, and lymphangiosarcoma; potentially representing a continuum of pathological evolution.<sup>2</sup> They can be subdivided into micro- and macrocystic, corresponding to a cyst size less than or greater than 1 cm, respectively.<sup>3</sup> These lesions can be solitary or multifocal, with waxing and waning growth patterns.<sup>3</sup> The most common location of LMs is the head and neck region, but they can also occur on the trunk, extremities, face, or oral cavity.<sup>2,3</sup> Occasionally, the lesions can be painful and/or bleed; additionally, they have been associated with lymphopenia, leading to a higher risk of infections for these patients.<sup>1</sup>

The mortality rate of this pathology varies from 3.4 to 5.7%.<sup>3</sup> Lymphangiomas can be nicely defined on CT or MRI, and ultrasound should be carried out as well for a thorough work-up. In the past, surgery was the obvious treatment of choice with regard to lymphangiomas. Recently, an increasing number of studies have suggested more conservative, and possibly safer, management alternatives to surgery, but with mixed results. These include sclerotherapy, ultrasound-guided needle decompression of the cysts, or intralesional corticosteroid injections.<sup>2,6</sup>

Lymphangiomas are hypothesized to originate in locations corresponding to the six primary lymph sacs, secondary to closure of the embryological lymphatic tissue and of parts of those primitive sacs, which arise during the fifth week of gestation.<sup>3,4</sup> This particular case, and other cervicofacial LMs, most likely arose from the jugular sac.

As seen with our patient, these lesions tend to present as soft, doughy, poorly defined, and with intralesional hemorrhage. When the LM reaches a significant size, it may be subject to trauma, bleeding and infection. Though sometimes uninvolved, the overlying skin may demonstrate some lymphatic papules, or vascular cutaneous marks.<sup>1</sup> In addition, the skin color may have a blue shade to it, especially when the LM is macrocystic, or it may appear as a dark-red dome after intralesional hemorrhage. Internally, these masses are uni- or multi-loculated, with very thin walls. The cystic cavities contain clear, proteinaceous, serous fluid, which is highly concentrated in lymphocytes and macrophages.<sup>1</sup>

In fact, 45% of such stable lesions have shown spontaneous regression.<sup>1</sup> If intervention is needed, the standard treatment for LMs used to be surgery, since a complete resection would almost guarantee elimination of any risk of recurrence. However, the main limitation with this approach was the potential damage to nearby vital structures.<sup>2,3,5-7</sup> Subtotal resection increased the already high recurrence rate (15-53%).<sup>3,4,6</sup> Intralesional injection of triamcinolone acetonide may offer a better option for presurgical treatment and improve the likelihood of complete resection of the lesion. The challenge for such a small baby is significant blood loss during surgery. Preoperative intralesional triamcinolone injections were very helpful in reducing the size of lesion in this infant, thus, minimizing surgical complications.

One case of tongue lymphangioma achieved a 90% regression and fewer bleeding episodes after intralesional steroid injections at 3-week intervals.<sup>2</sup> Similarly, an orbital lymphangioma regressed successfully with systemic corticosteroids.<sup>8</sup> The treatment time in the pediatric population should be very limited, since it may suppress adrenal function, thus leading to a risk of growth retardation.<sup>8</sup> In our case, the child's growth rate was considered to be normal at the age of 4 years, with a height of 92.5 cm. The injections should be followed with surgical resection, once the lesion regresses to an operable size. Steroids are believed to inhibit the inflammatory response by diminishing the production of many cytokines, as well as of PDGF A and B, IL-6, TGF-beta 1 and 3, leading to a decrease in mass effect from the hypertrophy of the lymphoid tissue.<sup>2,8</sup> In addition, steroids may contribute to a decrease in spontaneous hemorrhages

by stabilizing the vasculature and inducing involution of vascular malformations.<sup>8</sup> Nonetheless, not every child responds to the treatment, and some cases have been reported in which the patient's LM either did not improve or progressed, despite intralesional steroid injections.<sup>7</sup>

Finally, other treatment options are electrocoagulation, cryosurgery, and laser surgery, if surgical treatment of lesions has a high risk of resulting in functional disability.

In conclusion, intralesional injections of triamcinolone acetonide may be an option for presurgical treatment. Short term use of preoperative intralesional triamcinolone injections was helpful for decreasing lesion size, thus reducing blood loss and improving the chances of complete resection of the lesion.

### Conflict of Interest.

None declared.

### References

1. Bagrodia N, Defnet AM, Kandel JJ. Management of lymphatic malformations in children. *Curr Opin Pediatr*. 2015;27:356–63.
2. Khurana S, Vij A, Singal A, Pandhi D. Lymphangioma of the tongue: response to intralesional steroids. *J Dermatolog Treat*. 2006;17:124–6.
3. Farnoosh S, Don D, Koempel J, Panossian A, Anselmo D, Stanley P. Efficacy of doxycycline and sodium tetradecyl sulfate sclerotherapy in pediatric head and neck lymphatic malformations. *Int J Pediatr Otorhinolaryngol*. 2015;79:883–7.
4. Alvi A, Mysiorek D, Reppucci A. Unusual presentations of lymphangioma. *Arch Otolaryngol Head Neck Surg*. 1993;119:1358–61.
5. Grasso DL, Pelizzo G, Zocconi E, Schleef J. Lymphangiomas of the head and neck in children. *Acta Otorhinolaryngol Ital*. 2008;28:17–20.
6. Okazaki T, Iwatani S, Yanai T, Kobayashi H, Kato Y, Marusasa T, et al. Treatment of lymphangioma in children: our experience of 128 cases. *J Pediatr Surg*. 2007;42:386–9.
7. Tawfik HA, Budin H, Dutton JJ. Lack of response to systemic corticosteroids in patients with lymphangioma. *Ophthal Plast Reconstr Surg*. 2005;21:302–5.
8. Sires BS, Goins CR, Anderson RL, Holds JB. Systemic corticosteroid use in orbital lymphangioma. *Ophthal Plast Reconstr Surg*. 2001;17:85–90.