

Case Report

Giant brain aneurysm in a two-year-old girl

Prastiya Indra G, Hapsari Kusumawardani, Darto Saharso

Brain aneurysm is an abnormal outward bulging of one of the brain arteries. Brain aneurysms are often discovered when they rupture, causing bleeding into the brain or the space surrounding the brain called the subarachnoid space. This subarachnoid hemorrhage can lead to hemorrhagic stroke, brain damage and death.¹

The aneurysm can present in all ages, but mainly after 50 year of age (ages 35 – 60), and exists a greater predisposition in females, with a ratio 3:2.² Intracranial aneurysms in children are rare. About 0.5-4.6% of all aneurysms in children distinctly differ from adult, especially in male (2:1 to 3:1).^{3,4,5,6}

These injuries are located mainly in any cerebral artery specifically in those related to the well-known Circles of Willis such as internal carotid, middle cerebral and anterior cerebral artery as well as anterior communicating artery that corresponds to anterior circulatory circuit. In the posterior region they can be observed above the posterior cerebral artery, vertebral and basilar arteries, mainly. Aneurysm in children is mostly located at the bifurcation of ICA or vertebra-basilar artery posterior circulation, yet disproportionately with high incidence of posterior circulation aneurysm (40-50%) and of giant aneurysm (30-45%).⁷

The purpose of this paper is to present a case of giant brain aneurysm in a two year old girl, focusing on diagnostic and management approach.

The Case

A two year old girl was referred from Neurologist at Bojonegoro General Hospital on December 17th

2008, with a working diagnosis of Arterio-Venous Malformation DD/ Meningoencephalitis. The main complaint was profuse vomiting since five months ago. The patient had history of vomiting since she was a baby, which was not frequent at the first year of life and had been getting worse since five months ago. The vomit was profuse and was more frequent, 3 times a day, usually after eating or drinking and did not correlate to cough or position. The complaint was followed by bulging of the left eye since five months ago. She had already taken to the ophthalmologist and given eye drop, but there was no improvement. She also looked weak and could not concentrate well. There were no fever, seizure and dyspnea. There was no history of seizure and trauma before.

The patient was born spontaneously by a healthy mother in full term pregnancy, assisted by a doctor, and cried spontaneously after the birth. Her birth weight was 3500 gram. She was breastfed until admitted to the hospital. She only received DPT and Polio I immunization. The development was normal before the symptom occurred. She could sit when she was eight month old, stand in two months after that, and able to walk by herself when she was 12 month-old. She could speak few words when she was 18 month-old. Since four months ago, the lower extremities were getting weak

From the Department of Child Health, Medical School, Airlangga University, Surabaya, Indonesia.

Reprint requests to: Prastiya Indra Gunawan, Dr. Soetomo Hospital of Pediatric Department, Mayjen Prof. Dr. Moestopo- Str. 6-8, 60286 Surabaya, Surabaya. E-mail: prastiya_ig@yahoo.co.id

and she looked shiny. She was a second child in the family. No similar history was found in her sibling.

Physical examination showed an alert girl with body weight 8 kg, body height 74 cm and head circumference 49 cm. The pulse rate was 112 beats per minute, the respiratory rate was 28 times per minute and the body temperature was 37°C. No anemia, cyanosis, icterus and dyspnea were observed. There were proptosis and lagophthalmos in the left palpebra, and “cork screw” appearance in the left conjunctiva. Chest examination showed no retraction. Heart sound was normal, no murmur was noted. Lung sound was symmetrically vesicular, no rales and no wheezing. On inspection, the abdomen was flat, no bowel movement or bowel contour was found. Bowel sound was normal.

On palpation, no particular abnormality was found on all parts of the abdomen. Skin turgor was normal. No abdominal muscle rigidity, rebound tenderness, or meteorismus was noted. Liver and spleen were not palpable. The extremities were warm and no edema.

The neurologic examination showed patient with PCS E4M5V5, normal pupil with Ø 3mm of both eyes and light reflect was normal. No meningeal signs. Sensory nerve was normal, upper motoric extremities were normal but lower motoric extremities were weak. Physiologic reflex was positive normal and there was no pathological reflexes.

The laboratory examination showed: hemoglobin 10.7 g/dL, white blood cell 4000/cmm, hematocrit 30 %, platelets 210000/cmm. Blood sugar was 106 mg/

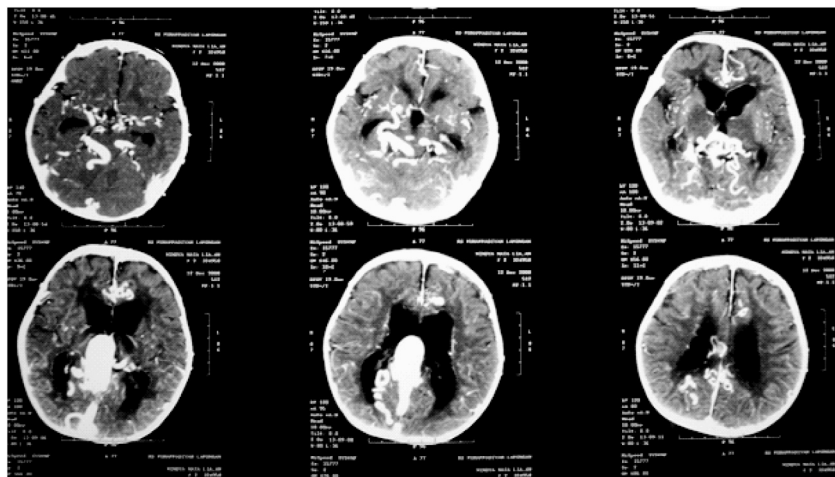
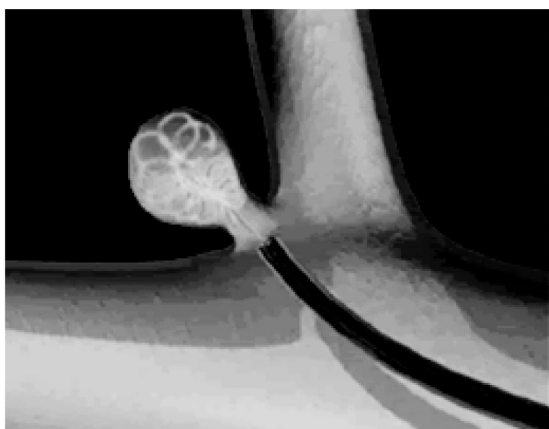
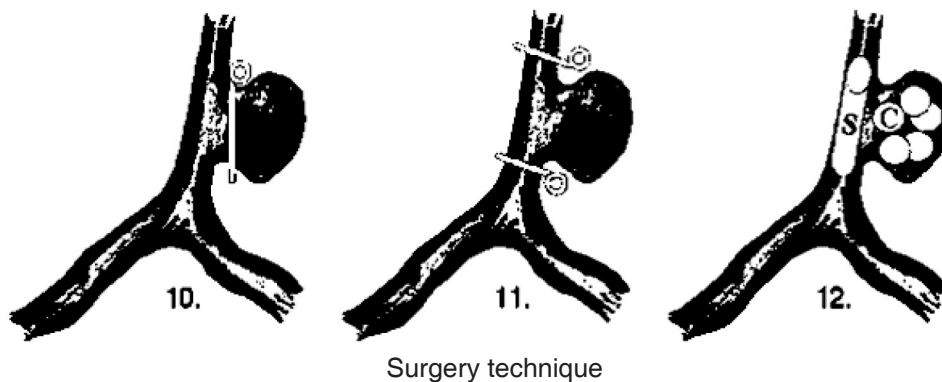


Figure 1. The head CT Scan of the patient

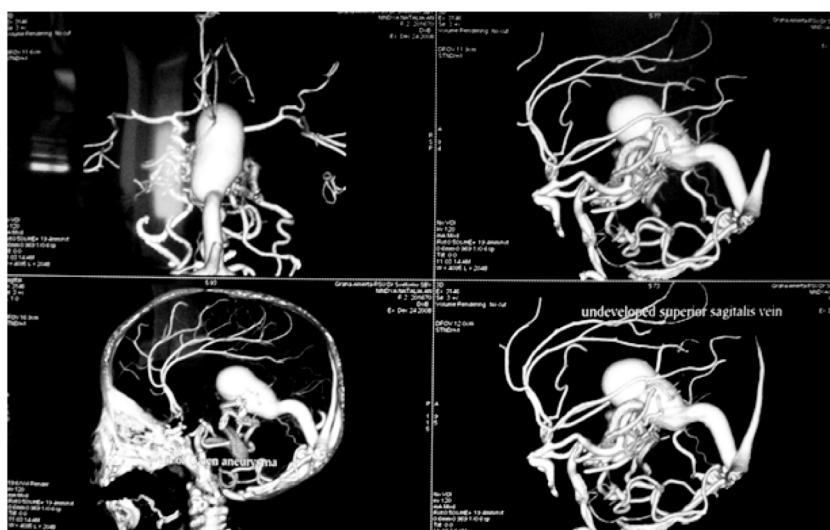

Figure 2. The CT Angiography of the patient



Endovascular Coiling Technique



dL, ALT 37 IU, AST 8 IU, total bilirubin was 0.72 mg/dL with direct bilirubin was 0.13 mg/dL and serum albumin 5.14 g/dL. The renal function tests revealed BUN 7 mg/dL and serum creatinin 0.4 mg/dL. The serum potassium 4.11 mEq/L, serum sodium 136.1 mEq/L, serum calcium 10.4 mEq/L and serum chloride 90.3 mEq/L. Hemostatic function PPT 10.0 second with control 10.8 second and APTT 31.0 second with control 28.5 second.

The chest X-ray was normal. The CT scan of the head showed generalized brain atrophy + posterior cerebral media artery aneurysm, suspicious Giant aneurysm (**Figure 1**).

The patient was diagnosed as a suspected Giant Aneurysm and was given IVFD D5 ¼ S 300cc/24 h and ondancetron injection 3 x ¼ vial for the vomiting.

We consulted the patient to the ophthalmology Department for the possibility of visual disturbance resulted from corneal injury due to exposed conjunctivitis and with history of proptosis in the left eye. From the examination of the visus, revealed

positive response to light and environment. The ocular pressure of both eyes was normal. The left palpebra was proptosis, lagophthalmus, and bruit. There was a “cork screw” appearance in the left conjunctiva without hyperemia. The cornea, iris, pupil and lens were normal. The oculomotor were

normal. Funduscopy revealed normal fundus reflex, with normal papil N.II, no bleeding and exudate of the retina, and normal macular reflex. CT Angiography was performed on the sixth day of hospitalization, with the results of: 1) Vein of Galen aneurysm Mural type, 2) Undeveloped sinus sagital superior-inferior and internal cerebral vein (+), 3) Dilated superior ophthalmic vein cause by venous outlet obstruction, 4) Obstructive hydrocephalus with periventricular leucomalacia (**Figure 2**).

Based on the CT Angiography, the neurosurgeon confirmed the diagnosis of Giant Aneurysm and Obstructive hydrocephalus. They planned to perform coiling therapy.

Discussion

A two year old girl was presented in this case with the main complaint of profuse vomiting. From the history taking we found history of vomiting since she was a baby, and were getting worse about 4-5 months ago. Followed by other complaints of bulging left eye, lethargic and did not concentrate well. The patient was delivered spontaneously and the development milestones were normal until the symptoms occurred. Physical examination showed an apathetic girl, weak, proptosis and hyperemia conjunctiva of left eye. Laboratory examinations revealed anemia, with normal count of white blood cell and platelets. Her nutritional status was 83% of IBW. From the CT scan showed generalized brain atrophy + posterior cerebral media artery aneurysm, suspected Giant aneurysm.

Prevalence of the brain aneurysm was up to 5 - 10 % of the general population. On average, there are 10 cases of rupture of brain aneurysm per 100,000 of the general population per year. The incidence of large or giant aneurysm in children is higher than in adults whereas the rupture of aneurysm is stated inversely, thus leading to a relative low death rate within 48 hour after onset of the disease. Rupture of brain aneurysm is associated with a high rate of death and serious disability.⁸

The prognosis of the aneurysm depends on the extent, location, age, general health, and neurological condition. There are patients with cerebral aneurysm died from the initial bleeding. Meanwhile others have been gaining recovery with little or no neurological

deficit. Generally, about two third of patients have a poor outcome, death, or permanent disability.⁹

Vomiting, which was a main complaint of this patient, is a forceful ejection of stomach or esophageal contents from the mouth. Vomiting should be approached by identifying the pattern. The review of systems should include other abdominal, respiratory, and neurologic complaint. The vomiting related to the abdominal complaint usually include in acute condition, in the context of an acute abdomen. The vomiting, associated with respiratory system, is usually followed by complaint of nausea, congestion, postnasal drip, and early morning occurrence proceeded by coughing. From the neurologic complaint, signs and symptoms suggestive of increased intracranial pressure include early morning occurrence, progressive headaches, absence of nausea, and abnormal funduscopic examination.¹⁰

Vomit may be acute or chronic. In acute condition, in the context of an acute abdomen, immediate surgical consultation should be obtained. Sign and symptom of an acute abdomen include sudden severe pain, bilious vomiting, point or diffuse tenderness on examination, diarrhea with abdominal distention, absent bowel sounds, rebound tenderness, rigid abdomen and pain with movement or cough. In chronic recurrent vomiting, which frequency about two episodes per week, abdominal pain and diarrhea are frequently associated; children are not acutely ill and vomit with a low intensity. The signs or symptoms of chronic recurrent vomiting related with increased of intracranial pressure should be confirmed by head CT or MRI.

In this case, the patient had experienced a profuse vomiting since five months ago, three times a day, which was usually after eating and drinking.. The patient looked weak and did not concentrate well. No history of post nasal drip, congestion and coughing before. No complaint of an acute abdomen such as severe pain, bilious vomiting, diarrhea with abdominal distention, rebound tenderness, rigid abdomen and pain with movement or cough. From physical examination, there was no local or diffuse abdominal tenderness and no absent of bowel sound. Based on these signs and symptoms, the abdominal or respiratory cause of vomiting is less likely. The chronic nature of the vomiting might be suggestive increased of intracranial pressure which can be

confirmed by head CT scan. The differential diagnosis of increased intracranial pressure are brain tumor, intracranial hemorrhage, arteriovenous malformation (AVM), hydrocephalus and aneurysm.

Brain tumor can present at any age, but tends to have a peak age incidence. Two thirds of all intracranial tumors occur in children between the age of two and 12 years. There are two distinct patterns of presentation: symptoms and signs of the increased intracranial pressure (ICP) and focal neurologic signs. Tumors produce symptoms and signs of increased ICP due to obstruction of cerebrospinal fluid pathways and the development of hydrocephalus. Increased ICP is characterized by headache in the morning, vomiting, seizures, diplopia and papilledema. The headache is described as dull, generalized, and steady, maybe intermitten and worsened by coughing or sneezing or during defecation. The headache is typically associated with vomiting, which often relieves the headache. Alteration of personality is often the first symptom of a brain tumor, irrespective of its location. In the beginning week or month before the discovery of the tumor, the patient may become lethargic, irritable, hyperactive, forgetful and low performance in academic. The neurologic examination shows diplopia, strabismus, nystagmus, and hemiparesis.¹¹ This case presented two year old girl with symptoms and signs of increased ICP such as vomiting, weakness, decrease of consciousness, with neurologic examination showed proptosis and decreased lower motor state. No history of headache and seizures. No of diplopia, strabismus, nystagmus, papilledema and hemiparesis were found. The personality of the patient did not change either.

Next differential diagnosis is intracranial hemorrhage. It may occur in the subarachnoid space, or may be primarily located in the parenchyma of the brain. Subarachnoid bleeding is characterized by severe headache, nuchal rigidity, and progressive loss of consciousness, while intracerebral bleeding is characterized by focal neurologic signs and seizures.¹¹ The patient did not show characterization of intracranial hemorrhage. No severe headaches and seizure, although she got decrease of consciousness but not progressive. The physical examination showed a girl with GCS E4M4V6, decreased of lower motor state and no nuchal rigidity.

Another differential diagnosis is AVM. It is a result from failure of normal capillary bed development

between arteries and vein during embryogenesis. AVM produces abnormal shunting of blood, causing an expansion of vessel and a space occupying effect of rupture of a vein and intracerebral bleeding. AVM are typically located in the cerebral hemisphere, but they may be situated in the cerebellum, brain stem, or spinal cord. Rupture and bleeding can occur at any age. Children with AVM frequently have a history of seizures, migraine and headaches. Rupture of AVM causes a severe headache, vomiting, nuchal rigidity due to subarachnoid bleeding, progressive hemiparesis, and a focal or a generalized seizure.¹¹

The patient had no symptoms or signs of AVM. Next differential diagnosis is hydrocephalus. It is not a specific disease; it represents a diverse group of condition that resulted from impaired circulation, absorption and increased production of CSF. The clinical presentation of hydrocephalus is variable and depends on many factors, including the onset age, the nature of the lesion causing obstruction, and the duration and rate of the increased ICP. The cranial sutures are partially closed so that the signs of hydrocephalus may be more subtle. Irritability, lethargy, poor appetite, and vomiting are common to both age groups and headache is a prominent symptom in older patients.¹¹

From the head CT scan, we can conclude that there were generalized brain atrophy and posterior cerebral media artery aneurysm suspicious giant aneurysm. It was also confirmed by CT angiography (Figure 2).

Cerebral or brain aneurysm is a cerebrovascular disorder in which there is weakness in the wall of a cerebral artery or vein causes a localized dilatation or ballooning of the blood vessel.⁹ Brain aneurysms can occur in people of all ages, but are most commonly detected in those aged 35 to 60 year. In adult, women are actually more likely to have a brain aneurysm than men, with a ratio of 3:2.⁸ Intracranial aneurysms in the children are rare. About 0.5-4.6% of all aneurysms in children are distinctly differ from adult, especially in male (2:1 to 3:1).^{3,4,5,6}

Aneurysms in children younger than five years of age are rare. Most brain aneurysms are silent, the person totally unaware of a problem till the time of rupture. The symptoms may be a continuous morning headache, nausea, lost of function in one or more of the nerve bundles in the brain or spinal cord (e.g.

facial muscles weakness, double vision, impaired balance or hearing, tongue deviation, and weakness in the limbs, etc). At the time of rupture, the patient experiences one or more of the following: a sudden, extremely severe headache, vomiting, neck stiffness, loss of consciousness, sudden loss of function in one or more parts of the body, or a seizure.¹²

The most common site of aneurysm in the pediatric group is ICA bifurcation (20-50% of pediatric cases), while in adult is anterior communicating artery complex. The other common site is the middle cerebral artery. The reason for ICA bifurcation being the most common site in children is possibly due to the presence of a wide angle in ICA bifurcation. This angle exposes a wider area of vessel wall to the turbulent blood flow predisposing to aneurysm formation. Involvement of the posterior circulation in the pediatric population is quite varied, ranging from 4-16% in some series to 30-57% in others.^{12b} This case revealed a posterior cerebral media artery aneurysm, specifically at basilar artery.

Brain aneurysms can also be classified according to the size. The most common one, which is so called as "small", is 10 mm or less in diameter. "Giant" aneurysm is 25 mm or greater in diameter, while 11 to 15 mm and from 20 to 24 mm in diameter are "large" and "near-giant" aneurysm, respectively. There is a gray area of classification between 16 to 19 mm. Of all aneurysms, 95% are less than 25 mm in diameter; only 5% are "giants". In pediatric aged group, incidence of giant aneurysm was 30-45%.⁸ According to the CT Angiography of the patient, the size of aneurysm in this patient was 4.42 x 2.25 x 3 cm, which was more than 25 mm and was considered as "giant" aneurysm.

The main problem or complication of brain aneurysm is its expansion and rupture. If a brain aneurysm ruptures, the main complications are death and serious disability from the initial rupture itself or due to events occurring after the initial rupture. Of these events, the two most important are "rebleeding" of the ruptured aneurysm, and permanent brain tissue injury from cerebral vasospasm. The ruptured aneurysm can also cause several degree of obstruction of cerebrospinal fluid (CSF) flow in the brain (hydrocephalus). This is caused by the blood clot or blood products clogging up the CSF drainage system, and it can lead to progressive, permanent brain injury. Also, part of the brain can become electrically

irritated, resulting in seizures.⁸ Meanwhile, the expanding aneurysm may cause a pressure to the area around the aneurysm and increase the ICP. The CT Angiography shows obstructive hydrocephalus, which may be caused by the expanding aneurysm.

The best treatment for an aneurysm depends on the condition of the patient, the anatomy of the aneurysm, the ability of the surgeon, and must be weighed against the natural history of the condition. When treatment is indicated, surgical "clipping" of the aneurysm at the neck to exclude it from the circulation is considered to be the optimal treatment for most ruptured aneurysm. The ideal goal of surgical treatment is usually to place a clip across the neck of the aneurysm to exclude the aneurysm from the circulation without occluding normal vessels. When the aneurysm cannot be clipped because of the nature of the aneurysm, or poor medical condition of the patient, the medical treatment will be considered. The medical management includes control of blood pressure, calcium channel blockers, stool softeners and bedrest. The endovascular and other "nonsurgical" techniques to treat the aneurysm such as trapping, proximal ligation, and thrombosing aneurysm with Guglielmi detachable coils or ballon embolization.^{13,14}

Based on the condition of the patient, the anatomy and location of the aneurysm, this patient was planned to do the coiling technique by neurosurgery department.

The prognosis of the aneurysm depends on the patient's state in the moment before the surgical treatment.² Generally, about two thirds of patients have a poor outcome, death, or permanent disability.⁹ In many series, it was found that children tend to present in better clinical grades after aneurysm rupture and hence the outcome is better as compared to adults. The better functional capacity of brain and a better vascular status with greater collateralization of the vessels distal to the site of aneurysm in children may also account for a better outcome.¹²

This patient was in poor prognosis because the giant aneurysm had already made intracranial pressure which showed from the weakness, vomiting and decreased of consciousness. Although the patient did not show signs and symptom of ruptured aneurysm, it might be happened if the aneurysm still grow and the coiling therapy didn't performed as soon as possible.

In conclusion, a case of Giant Brain Aneurysm in 2 year old girl has been presented. The main complaint was profuse vomiting followed by weakness, proptosis of the left eye and could not concentrate well. It might be happened because of increased intracranial pressure. The CT scan and CT Angiography showed a giant aneurysm with the size 4.42 x 2.25 x 3 cm and obstructive hydrocephalus as a complication. Coiling techniques was performed by the neurosurgery department. The prognosis of the patient was bad because the age of the patient, the size of the aneurysm, the complication and the delayed treatment.

References

1. American Society of Interventional & Therapeutic Neuroradiology. Brain aneurysm [homepage on the internet]. Available from: <http://www.brainaneurysm.com/index.html>.
2. Ulloa MI. Cerebral aneurysms [homepage on the internet]. c2007-2009. Available from: <http://www.marioizurieta.com/en/procedures.htm>
3. Osenbuch RK. Giant aneurysm of the distal posterior inferior cerebellar artery in an 11-month-old child presenting with obstructive hydrocephalus. *Pediatr Neurosci*. 1989;15:309-12.
4. Ostengaard JR, Voldby B. Intracranial arterial aneurysms in children and adolescents. *J Neurosurg*. 1983;58:832-7.
5. Patel AN, Ricardson AE. Ruptured intracranial aneurysms in the first two decades of life. *J Neurosurg*. 1971;35:571-6.
6. Ciceri EFM, Lawhead AL, Simone TD, Valvassori L, Boccardi E. Spontaneous partial thrombosis of a basilar artery giant aneurysm in a child. *Am J Neuroradiol*. 2005;25:56-7.
7. Ketan D, Trimurti N, Dattatraya M, Atul G. Rupture of giant superior inferior cerebellar artery aneurysm in an infant following a ventriculoperitoneal shunt. *Neurol Meds Chir*. 2001;41:127-30.
8. G Khurana. Brain aneurysm [homepage on the internet]. c2010. Available from: <http://www.brain-aneurysm.com/ba2.html>
9. Young N. Cerebral aneurysm. Available from: <http://www.wiki.musialek.org/w/index.php/cerebrovascular-disease>.
10. Albert JP, Sharon L, Swapna S, Richard EB, Robert MK. Vomiting in gastrointestinal system. Pediatric decision-making strategies to accompany. In: Richard E. B, Robert M. K., Hal B. J, editors. *Nelson textbook of pediatrics*. 16th Ed. Philadelphia: Elsevier, 2002;p.78-85.
11. Haslam RHA. Brain tumors in children. The nervous system. In: Richard E. B, Robert M. K., Hal B. J, editors. *Nelson textbook of pediatrics*. 16th Ed. Philadelphia: Elsevier, 2000;p.1858-62.
12. Wani AA, Behari S, Sahu RN, Jaiswal AK, Jain VK. Paediatric intracranial aneurysm. *J Pediatr Neurosci*. 2006;1:11-5.
13. Bryce W, Macdonald RL. Intracranial aneurysm and subarachnoid hemorrhage: an overview. Aneurysm and subarachnoid hemorrhage. In: Wilkins RH, Rengachary SS, editors. *Neurosurgery*. 2nd Ed. USA: Mc Graw Hill, 1996;p.2191-213.
14. Greenberg MS. SAH and aneurysm. In: *Handbook of neurosurgery*. 5th Ed. USA: Thieme, 2001; p. 771-93.